



Effects of Ammonium Chloride on Some Vital Organs of Snakehead Fish, *Channa punctatus* (Bloch.)

Sameen Anjum ^{a++*} and Arti Kumari ^a

^a Department of Zoology, C.M.Sc. College, L.N.M.U., Darbhanga, India.

Authors' contributions

This work was carried out in collaboration between both authors. Both authors read and approved the final manuscript.

Article Information

DOI: <https://doi.org/10.56557/upjoz/2024/v45i144182>

Open Peer Review History:

This journal follows the Advanced Open Peer Review policy. Identity of the Reviewers, Editor(s) and additional Reviewers, peer review comments, different versions of the manuscript, comments of the editors, etc are available here: <https://prh.mbimph.com/review-history/3633>

Original Research Article

Received: 12/04/2024

Accepted: 16/06/2024

Published: 24/06/2024

ABSTRACT

The present study includes the chronic exposure of sublethal concentrations (20 mg/L) of inorganic fertilizer, ammonium chloride for 30 days to snakehead fish, *Channa punctatus* caused histopathological alteration in some vital organs. There were very significant histopathological changes were observed in gill, liver, intestine and kidney of treated fish group. The ammonium chloride treated fish group showed lamellar fusion, deterioration of secondary lamellae, hemorrhage and destruction of gill arches in gill. The remarkable changes like hyperemia, vacuolar degeneration, necrosis and mononuclear cells filtration in portal regions were observed in liver of treated fish group. The very distinguish alterations like hydropic degeneration, necrosis, desquamation in epithelium cells at the apex of the villi and mononuclear cell infiltration in the lamina propria were observed in kidney and proximal and distal tubules cellular shrinkage, nuclear pycnosis, and vacuolar degenerative changes in the tubular epithelium were observed in treated

⁺⁺ Research scholar;

^{*}Corresponding author: Email: sameen55anjum@gmail.com;

Cite as: Anjum, Sameen, and Arti Kumari. 2024. "Effects of Ammonium Chloride on Some Vital Organs of Snakehead Fish, *Channa Punctatus* (Bloch.)". *UTTAR PRADESH JOURNAL OF ZOOLOGY* 45 (14):94-101. <https://doi.org/10.56557/upjoz/2024/v45i144182>.

fish group. The finding of present investigation clearly analyzed that ammonium chloride caused dysfunction of some vital organs of *C. punctatus*. The study suggested that contamination of fertilizer, ammonium chloride in fish culture pond water should be avoided to fish production.

Keywords: *Channa punctatus*; ammonium chloride; nitrogenous fertilize; histopathology; agrochemical wastes.

1. INTRODUCTION

“The pollutants produced from agricultural activities caused loss of biological diversity is one of the most serious global environmental problems. Such anthropogenic activities now considered as threaten many species on the verge of global extinction” [1]. “The indiscriminate use of fertilizers in field could be a source of the surface water pollution due to run-off of these fertilizers. The contaminated water with such toxicants caused mortality of aquatic organisms especially fish. Fish are susceptible to such pollutant when the inhabitant region gets polluted such organisms are not able to escape from the deadly effects of pollutants” [2].

Ammonium chloride is a nitrogenous fertilizer widely used by farmers as a synthetic chemical in agricultural areas to enhance soil fertility [3]. “Ammonium chloride is soluble in water. In water it releases ammonia which is the main inorganic form of nitrogen” [4]. “Aquatic systems can have ammonium concentrations high enough to adversely impact fish as result of run-off of fertilizers or other sources. Ammonia (NH₃) is a natural byproduct of amino acid metabolism and, because it is a base, it rapidly accepts an H⁺ ion to form ammonium (NH₄⁺) at physiological pH” [5]. “Ammonia as well as ammonium is toxic when accumulated in body. So, an effective excretion system is essential to maintain cellular physiology. The ammonium contaminated water impacts may be detected on fish as decreased growth; changes fish behaviour and increased vulnerability to disease” [6,7,8,9].

Hence, the present study an effort has been made to understand the changes in histology of some vital organs of snakehead fish, *Channa punctatus* exposed to chemical fertilizer, ammonium chloride.

2. MATERIALS AND METHODS

The air-breathing, snakehead fish, *Channa punctatus* has average length (8–10 cm) and weight (30–34 g) was procured from local fish

market, Darbhanga and brought to the laboratory into an aerated plastic container. The healthy fish were washed with 0.4% KMnO₄ solution to avoid external infection. In the laboratory conditions fish were acclimatized for 15 days. Fish were fed the commercial feed (28% crude protein) with daily ration rate 3% of body weight once a day. The physico- chemical parameters of the water quality was maintained (follows the methods of APHA, [10]).

The acute bioassay LC₅₀ values of ammonium chloride were determined; the mortality was recorded after 24, 48, 72 and 96 hour and the LC₅₀ values for these periods were 300 mg, 260 mg, 225 mg and 200 mg respectively. The concentration was calculated by the Finney method [11]. The sublethal concentration was determined by Sprague, [12] method as 1/10th value of the LC₅₀ value for 96 hr was taken. Twenty fish were treated for 30 days and simultaneously normal fish taken for 30 days. On 30th day completion of exposure period fish were sacrificed and various organs were dissected out like gill, liver, kidney and intestine.

The different dissected organs, gill, liver, kidney and intestine from treated as well as control were cut into small pieces and tissue blocks with paraffin wax followed standard Luna method [13]. The thin sections (5-7 μm) were formed by microtome. The slides were prepared by mounted the sections and stained with hematoxylin and eosin. The slides were viewed under OLYMPUS microscope (X40) and microphotographs were taken for further histopathological analysis.

3. RESULTS

The histopathological alteration was observed in gill, liver, intestine and kidney of snakehead fish, *C. punctatus* induced to ammonium chloride sublethal concentration (20 mg/l) for 30 days.

Gill: The gill of normal structure *C. punctatus* exhibits typical teleostean plan. The gills comprises of primary and secondary gill lamellae

composed of cartilaginous skeletal structure, multilayered epithelium and vascular system. The primary gill lamellae are flat leaf-like structures arranged in double rows, projecting on the lateral sides of which are series of alternately arranged secondary lamellae are lined by squamous epithelium supported by pillar cells (Fig. 1). "The gill of fish exposed to sublethal 20 mg/l concentrations of ammonium chloride after 30 days showed significant alteration in form of lamellar fusion, deterioration of secondary lamellae and gill arch. Damage of lamellae, gill filament and test buds apparently changed, hemorrhage and destruction of gill arches were observed in treated group" [14] (Fig. 2).

Liver: In the present histological observation the liver of control fish, *Channa punctatus* showed hepatocytes are polygonal in shape with granular cytoplasm and centrally placed nuclei with densely stained nucleolus, systematically arranged narrow blood sinusoids. The liver is richly supplied by blood vessels (Fig. 3). After 30 days of the exposure of fish to 20 mg/l ammonium chloride resulted changes in the liver tissue like hyperemia, vacuolar degeneration, necrosis and mononuclear cells infiltration in portal regions (Fig. 4).

Intestine: The normal snakehead fish, *Channa punctatus* showed four layers of histology of intestine i.e., mucosa, submucosa, muscularis and serosa. The innermost layer is mucosa composed of columnar epithelial cells, which protrude into a number of folds known as villi, which has distinct mucous secreting cells and brush border cells. The second layer submucosa comprise of loose connective tissue, forms the

lamina propria of the villi. It has granular and richly vascular structure. The third layer muscularis has inner thick circular and outer thin longitudinal muscles. The outermost layer serosa comprise of thin vascular covering (Fig. 5). The treated fish group (30 days of the exposure of fish to 20 mg/l ammonium chloride) was observed histological changes in the intestine like, hydropic degeneration, necrosis, desquamation in epithelium cells at the apex of the villi and mononuclear cell infiltration in the lamina propria and desquamation mononuclear cell infiltration (MHI) in connective tissue (Fig. 6).

Kidney: The kidney of normal structure *C. punctatus* exhibits typical teleostean parts consists of head and body kidneys (Fig. 7). Head kidney is composed of lymphoid tissue situated at anteriorly. The nephrons and interstitial haemopoietic tissue are forming body kidney. The body majorly formed of interstitial and hematopoietic tissue. Each nephron has formed of the urinary tubule and the glomerulus. The single layer of epithelial cells formed renal tubules and Bowman's capsule formed of an inner layer of single flat epithelia.

The snakehead fish, *C. punctatus* exposed to 20 mg/l ammonium chloride for 30 days resulted histopathological changes in kidney as the glomerular tufts became melanized highly, proximal and distal tubules showed cellular shrinkage and nuclear pyknosis, hematopoietic tissues were enlarged and occupied wide area between the tubules and vacuolar degenerative changes in the tubular epithelium and slight congestion were observed (Fig. 8).

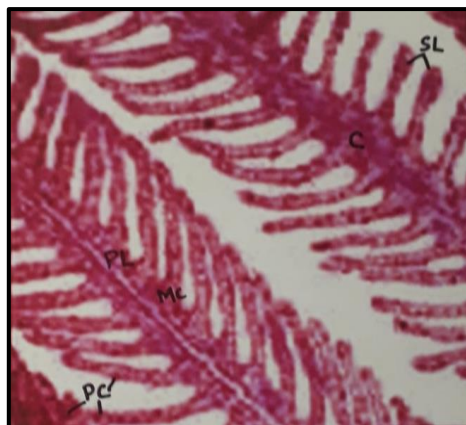


Fig. 1. Photomicrograph of normal gill of *Channa punctatus*. PL= Primary gill lamellae, SL=Secondary gill lamellae, PC= Pillar cells, MC= Mucous cells. X40

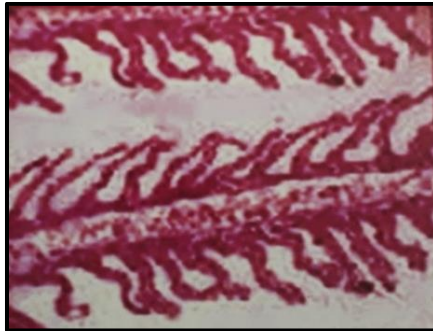


Fig. 2. Photomicrograph of gill of *Channa punctatus* exposed to 20 mg/l ammonium chloride for 30 days treated showed Fusion of Secondary Lamellae (FSL), Damage of Gill Lamellae (DGL), Gill Filament (GF) and Damage of Gill Arch (DGA).X 40

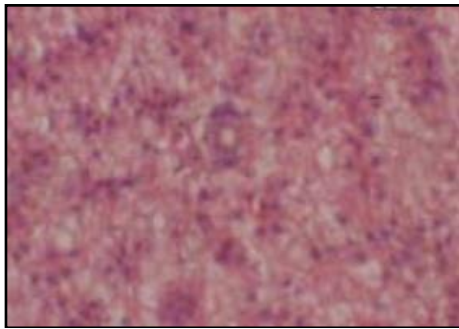


Fig. 3. Photomicrograph of normal of liver histology of *Channa punctatus* showed sinusoids (S), Blood vessels (BV). X40

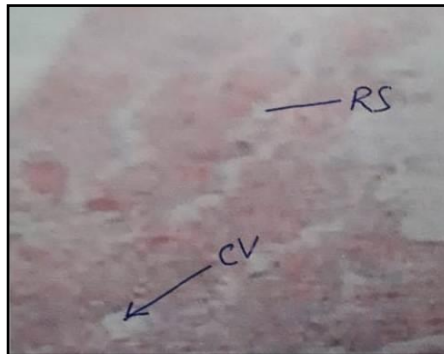


Fig. 4. Photomicrograph of liver of *Channa punctatus* exposed to 20 mg/l ammonium chloride for 30 days showed rupture of sinusoids (RS), Bile Duct (BD) and Central vessel (CV). X40

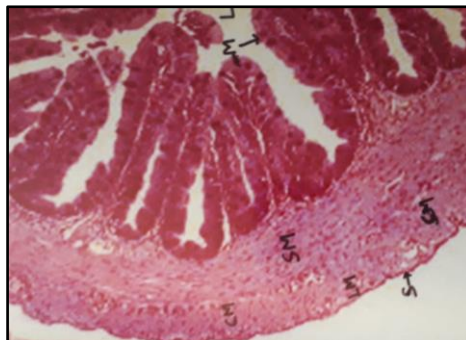


Fig. 5. Photomicrograph of normal intestine of *Channa punctatus* showed Circular muscular fibres (CM), sub-mucosa (SM), Mucosa (M), Lumen (L) and villi (V). X 40

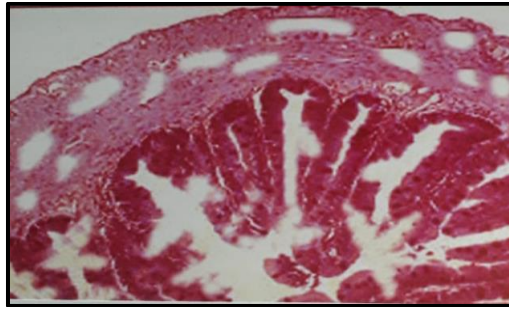


Fig. 6. Photomicrograph of intestine of *Channa punctatus* exposed to 20 mg/l ammonium chloride for 30 days showed mononuclear cell infiltration (MCI), degeneration and desquamation in villi (V). X40

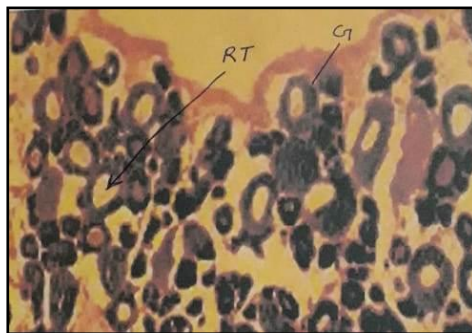


Fig. 7. Photomicrograph of normal kidney of *Channa punctatus* showed renal tubule (RT), glomerulus (G) and Bowman's capsule (BC). X40

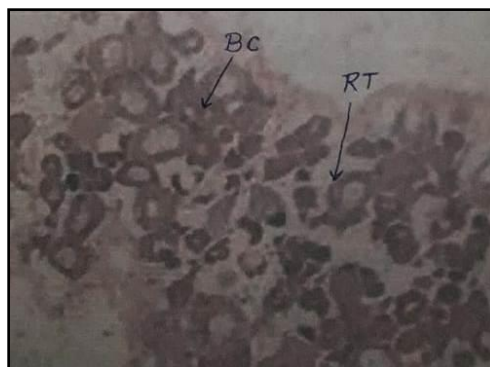


Fig. 8. Photomicrograph of kidney of *Channa punctatus* induced to 20 mg/l ammonium chloride for 30 days showed renal tubule (RT), glomerulus (G) and Bowman's capsule (BC). X40

4. DISCUSSION

The present investigation was undertaken the snakehead fish, *Channa punctatus* induced to fertilizer, ammonium chloride (20 mg/l) sublethal concentration for 30 days showed histopathological alteration in four organs like gill, liver, intestine and kidney. The present finding has been discussed here stepwise with similarity of earlier reports of workers of the relevant field.

Gills are come in contact with contaminants first. Due to that it became prime site of toxicant action. The status of gill reflects susceptibility of fish with toxicants. Yeldrim et al, [15] reported the histological alteration in gill of fish induced to pesticides Carbofuran. Velmurugan, [16] has found that "*Cirrhinus mrigala* exposed to various concentrations of dichlovos and organophosphate pesticide showed histopathological alterations in the gill, necrosis of epithelial, oedema, lameller fusion, collapsed

secondary lamellae and curling of secondary lamellae”.

Cengiz [17] has found that freshwater fish, *Cyprinus carpio* exposed to pesticide, deltamethrin showed histopathological changes in liver tissues. Matos et al. [18] have found that Nile tilapia, *Oreochromis niloticus* exposed to carbaryl showed histopathological changes in liver. Cattaneo et al, [19] have found that “histological alteration like fragmentation and rupture in cell membrane, vacuoles in sinusoids of the liver tissues of silver catfish exposed to pesticide”. Sepici-Dincel et al, [20] reported “the histopathological changes in liver of *O. niloticus* and *C. carpio* exposed to sub-lethal concentrations of carbaryl and cyfluthrin”. Velmurugan, [16] reported “the *Cirrhinus mrigala* exposed to various concentrations of dichlorvos and organophosphate pesticide showed the remarkable histopathological alterations in the liver tissues i.e. hyperplasia, congestion, vacuolar degeneration, karyolysis, karyohexis, dilation of sinusoids”. Ullah, et al. [21] postulated that “detoxification of the cypermethrin in liver causes necrosis, it could be due to the extra work load on hepatocyte when experimented with pesticides exposure in fish”. The liver considered as major metabolic site and any damage to this organ would subsequently do, so many physiological disturbances leading to subsequent mortality of fish suggested by Mishra & Poddar [22]. The present finding has similarity with above studies.

Sastri and Gupta [23] reported that *Channa punctatus* exposed to heavy metal mercuric chloride showed the proliferation, necrosis of serosa and mucosa and rupture of villi in intestine. Recently, Islam et al. [24] reported that *H. fossilis* induced to diazinon concentrations 25.0 mg/l showed histopathological changes like muscularis swollen, slightly damaged serosa, fused or ruptured villi in intestine and disintegrated sub-mucosa. Very recently, Kumari, et al. [25] reported that *Clarias batrachus* exposed to fertilizer, ammonium chloride showed histopathological alteration in intestine. The above reporting is similar to the present findings.

Rand and Petrocelli [26] found the necrosis in tubules, pyknosis and karyorrhexis in kidney tissues of Salmon induced to 100 ppm Amitrole for 144 hours. Rahman et al. [27] found histopathological changes in kidney, like tubules degenerated, necrosis and hemorrhage in kidney tissues of *Anabas testudineus*, *Channa*

punctatus and *Barbodes gonionotus* exposed to Diazinon 60 EC. Another study also showed similar histopathological changes like tubular fusion, epithelial hypertrophy, glomerular condensation, hemorrhage and necrosis of Bowman’s capsule in kidney of *Clarias gariepinus* exposed to pesticide, cypermethrin at different concentrations [16]. Boran et al, [28] found the remarkable histopathological changes like necrosis in epithelial cell in kidney of juvenile rainbow trout, *Oncorhynchus mykiss* exposed to maneb and carbarys. Recently, Nayan, et al. [29] have found the histopathological alteration like degeneration of renal tubule epithelia, hyaline droplet degeneration and renal failure in kidney of *Cyprinus carpio* exposed to Dimethoate (EC 30%).

5. CONCLUSION

In present study conclude that *Channa punctatus* with average weight 30.0 ± 4.0 g, were more susceptible to fertilizer, ammonium chloride at concentration of < 20 mg/l. The histopathological changes in gill, liver, intestine and kidney of fish were associated with toxic effects of fertilizer ammonium chloride. The study suggested that contamination of fertilizer, ammonium chloride in fish culture pond water should be avoided to fish production.

DISCLAIMER (ARTIFICIAL INTELLIGENCE)

Author(s) hereby declare that NO generative AI technologies such as Large Language Models (ChatGPT, COPILOT, etc) and text-to-image generators have been used during writing or editing of manuscripts.

ACKNOWLEDGEMENT

The authors are thankful to the Department of Zoology, C.M.Sc. college, LNM University, Darbhanga, Bihar for the provision of laboratory facilities used in this study.

COMPETING INTERESTS

Author has declared that no competing interests exist.

REFERENCES

1. Díaz S, Settele J, Brondízio E. Summary for policymakers of the global assessment report on biodiversity and ecosystem

- services of the Intergovernmental Science-Policy Platform on Biodiversity and Ecosystem Services; 2020.
2. Gbaruko BC, Friday OU. Bioaccumulation of heavy metals in some fauna and flora. *Int. J. Environ. Sci. Tech.* 2007;4(2):197-202.
 3. Naidu NG, Vijay Kumar PPN, Shameem U. Acute and sub-acute toxic effect of Ammonia on Behavioral and Haematological responses of Indian Major Carp *Labeo rohita* Ham, 1822. *International Journal of Fisheries and Aquatic Studies.* 2017;5(2):332-335.
 4. Clarkson DT, Hopper MJ, Jones LP. The effect of root temperature on the uptake of nitrogen and the relative size of the root system in *Lolium perenne*. I. Solutions containing both NH₄⁻ and NO₃⁻ Plant, Cell and Environment. 1989;535-545.
 5. Cameron JN, Heisler N. Ammonia transfer across fish gills: a review. In R. Gilles (ed.), *Circulation, respiration, and metabolism.* 1983;91/100. Berlin: Springer Verlag.
 6. Thurston RV, Russo RC, Luedtke RJ, Smith CE, Meyn EL, Chakaoumakos C, Wang KC, Brown CJD. Chronic toxicity of ammonia to rainbow trout. *Transactions of the American Fisheries Society.* 1984;113: 56-73.
 7. Ishaku AH, Jauro AI, Gadaka YM, Yagana A, Mohammed RA, Usman S, Chinda W. Toxicity Effects of Brown Dried Pawpaw (*Carica papaya*) Leaf Extract to Fingerlings of African Catfish *Clarias gariepinus*. *Asian J. Fish. Aqu. Res.* [Internet]. 2019 Sep. 7 [cited 2024 Jun. 3];4(3):1-8. Available: <https://journalajfar.com/index.php/AJFAR/article/view/67>
 8. Nasrin T, Saha AK, Mohanta MK, Chaity AS, Alam MJ, Shawon MMH, Haque MF. Reduction of Toxic Effects of Textile Dye, Basic Red-18 on Tilapia Fish by Bioremediation with a Novel Bacterium, *Mangrovibacter yixingensis* Strain AKS2 Isolated from Textile Wastewater. *Ann. Res. Rev. Biol.* [Internet]. 2022 Oct. 29 [cited 2024 Jun. 3];37(11):12-29. Available: <https://journalarrb.com/index.php/ARRB/article/view/1913>
 9. Yang C, Song G, Lim W. A review of the toxicity in fish exposed to antibiotics. *Comparative Biochemistry and Physiology Part C: Toxicology & Pharmacology.* 2020 Nov 1;237:108840.
 10. APHA. Standard methods for the examination of water and waste water (16th Ed). American Public Health Assoc., Washington D.C; 1985.
 11. Finney DJ. *Statistical methods in biological assay.* 3rd ed. London UK: Griffin Press; 1978;508.
 12. Sprague JB, Measurement of pollution toxicity to fish. III. Sub – lethal effects and ‘safe’ concentration, *Water Res.* 1971;5: 245- 266.
 13. Luna G. *Manual of histologic staining methods of the Armed Forces Institute of Pathology*, 3rd Edition, Mc Grow –Hill Book Company, New York; 1968.
 14. Anjum S, Kumari A. Histopathological changes in *Channa punctata* (Bloch.) induced to ammonium sulphate. *International Journal of Fisheries and Aquatic Studies* 2023;11(2):18-22.
 15. Yildirim MZ, Benli AC, Selvi M, Ozkul A, Erkoc F, Kochak. Acute toxicity behavioral changes and histopathological effects of deltamethrin on tissues (gills, liver, brain, spleen, kidney, muscle and skin) of Nile tilapia (*Oreochromis niloticus* L.) fingerlings. *Environ. Toxicol.* 2005;21(6): 614-620.
 16. Velmurugan B, Selvanayagam M, Cengiz EI, Unlu E. Histopathological changes in the gill and liver tissues of freshwater fish, *Cirrhinus mrigala* exposed to dichlorvos. *Brazilian Archives of Biology and Technology.* 2009, 52:1291-1296.
 17. Cengiz EI. Gill and kidney histopathology in the freshwater fish (*Cyprinus carpio*) after acute exposure to deltamethrin. *Environmental Toxicology and Pharmacology.* 2006;22:200-204.
 18. Matos P, Fontainhas-fernandes A, Peixoto F, Carrola J, Rocha D. Biochemical and histological hepatic changes of Nile tilapia *Oreochromis niloticus* exposed to carbaryl. *Pesticide Biochemistry and Physiology.* 2007;89:73-80.
 19. Cattaneo R, Loro VL, Spanevello R, Silveira FA, Luz L, Miron DS, Fonseca MB, Moraes BS, Clasen B.. Metabolic and histological parameters of silver catfish (*Rhamdia quelen*) exposed to commercial formulation of 2,4-dichlorophenoxyacetic acid (2,4-D) herbicide. *Pesticide Biochemistry and Physiology.* 2008;92: 133-137.
 20. Sepici-dincel A, Benli ACK, Selvi M, Sarikaya R, Sahin D, Ozkul IA, Erkoc R. Sublethal cyfluthrin toxicity to carp (*Cyprinus carpio* L.) fingerlings: Biochemical, hematological, histopatho-

- logical alterations. J. Ecotoxicol. Environ. Safe. 2009;72:1433-1439.
21. Ullah R, Zuberi A, Naeem, M, Ullah S. Toxicity to haematology and morphology of liver, brain and gills during acute exposure of mahseer (*Tor putitora*) to cypermethrin. International Journal of Agricultural Biology. 2015;17:199–204.
 22. Mishra A, Poddar A. Histopathology of the liver of Indian Murrel *Channa punctatus* (Bloch) exposed to Phenolic Effluents. International Journal of Research in Chemistry and Environment. 2016;6(4): 16-21.
 23. Sastri KV, Gupta PK. Effect of mercuric chloride on the digestive system of *Channa punctatus*: A histopathological study. Environmental Research. 1978;16: 270-278.
 24. Islam MS, Haque MM, Uddin MN, MD Hasanuzzaman. Histopathology in the fish *Channa punctatus*, *Heteropneustes fossilis* and *Anabas testudineus* exposed to diazinon. Inter. J. of Fisheries and Aquatic Studies. 2019;7(6):47-54.
 25. Kumari S, Anand K, Jha V. Toxicity of Ammonium chloride on fish behavior and histopathology of air breathing fish *Clarias batrachus* (Linn.). JETIR. India. 2020; (7)11.
 26. Rand GM, Petrocelli SR. Fundamentals of aquatic toxicology. Hemisphere Publishing Corporation, Washington. 1985;666.
 27. Rahman MZ, Hossain Z, Mollah MFA, Ahmed GU. Effect of Diazinon 60 EC on *Anabas testudineus*, *Channa punctatus* and *Barbodes gonionotus* Naga the ICLARM quarterly. 2002;25(2):8-12.
 28. Boran H, Altinok I, Capkin E. Histopathological changes induced by maneb and carbaryl on some tissues of rainbow trout (*Oncorhynchus mykiss*) Tissue Cell. 2010;42(3):158-164.
 29. Nayan SR. Histopathological alterations in the kidney of *Cyprinus carpio* after exposure to Dimethoate (EC 30%). Indian Journal of Scientific Research. 2012;3(1): 127-131.

© Copyright (2024): Author(s). The licensee is the journal publisher. This is an Open Access article distributed under the terms of the Creative Commons Attribution License (<http://creativecommons.org/licenses/by/4.0>), which permits unrestricted use, distribution, and reproduction in any medium, provided the original work is properly cited.

Peer-review history:

The peer review history for this paper can be accessed here:

<https://prh.mbimph.com/review-history/3633>