



Merkel Cell Carcinoma and the Innovative Immunotherapy: A Case Report

**Fernando Augusto Pacífico^{a++},
Ohanna Louise Vasconcelos de Aquino Santos^{a#},
Rafaella Monique de Aquino Lopes Melo^{a#},
Evely Figueiredo Feitoza^{a#},
Hanna Ravigna Duarte Sena e Silva^{a#},
Thiago José Monteiro Borges da Silva Valente^{a#*},
Ismael Felipe Gonçalves Galvão^{a#}
and Luciana Maria Queiroz de Oliveira Borges^{a++}**

^a *Faculty of Medicine of Olinda – FMO, Olinda, Pernambuco, Brazil.*

Authors' contributions

This work was carried out in collaboration among all authors. Authors FAP and LMQOB conceptualized the research work. Authors FAP and LMQOB did data curation. Authors FAP and LMQOB performed the methodology. Authors FAP and LMQOB did project administration. Authors FAP and LMQOB did data resources. Authors FAP and LMQOB supervised the study. Authors FAP, OLVAS, RMALM, EVF, HRDSS, TJMBSV, IFGG and LMQOB wrote original draft. Authors FAP, OLVAS, RMALM, EVF, HRDSS, TJMBSV, IFGG and LMQOB reviewed and edited the manuscript. All authors read and approved the final manuscript.

Article Information

DOI: <https://doi.org/10.9734/jammr/2024/v36i95580>

Open Peer Review History:

This journal follows the Advanced Open Peer Review policy. Identity of the Reviewers, Editor(s) and additional Reviewers, peer review comments, different versions of the manuscript, comments of the editors, etc are available here: <https://www.sdiarticle5.com/review-history/122570>

⁺⁺ Teacher;

[#] Student;

^{*}Corresponding author: E-mail: thiagovalentemed@gmail.com;

Cite as: Pacífico, Fernando Augusto, Ohanna Louise Vasconcelos de Aquino Santos, Rafaella Monique de Aquino Lopes Melo, Evely Figueiredo Feitoza, Hanna Ravigna Duarte Sena e Silva, Thiago José Monteiro Borges da Silva Valente, Ismael Felipe Gonçalves Galvão, and Luciana Maria Queiroz de Oliveira Borges. 2024. "Merkel Cell Carcinoma and the Innovative Immunotherapy: A Case Report". *Journal of Advances in Medicine and Medical Research* 36 (9):333-38. <https://doi.org/10.9734/jammr/2024/v36i95580>.

ABSTRACT

Aim: Reports a case of an 82-year-old male patient with metastatic Merkel Cells Carcinoma (MCC) and review the main aspects.

Presentation of the Case: In this study, the patient had a lesion on his face in the right frontal region, whose immunohistochemical study confirmed MCC, and he underwent exeresis of the tumor. After the appearance of new lesions in other locations, some of which were metastatic, radiotherapy was performed and, after that, immunotherapy, with the latter showing clinical improvement and remission of the lesions.

Discussion: Despite its rarity, there has been a growing incidence of MCC. Given the high immunogenicity of merkel cell polyomavirus and human polyomavirus form's, the need for therapies aimed at these mechanisms is confirmed. Immunotherapy, with avelumab for example, is making progress in the treatment of MCC, not only in terms of patient survival but also in terms of a better quality of life, especially in terms of psychological well-being and physical performance, as well as having fewer adverse effects compared to radiotherapy.

Conclusion: The immunotherapy is a promising option in the face of this challenging condition, particularly in the elderly and immunocompromised. The results after this treatment suggest the need for greater monitoring and research into its long-term effectiveness in the treatment of MCC, in addition to the search for validation of an approach that provides the patient with a better prognosis and greater quality of life.

Keywords: Merkel cell tumor; carcinoma; Merkel cell; skin neoplasms; case report.

1. INTRODUCTION

Merkel cell carcinoma (MCC) is a rare type of skin cancer that accounts for less than 1% of all skin malignancies and originates in the Merkel discs, epidermal structures with a mechanoreceptive function [1]. This pathology is most prevalent in Australia, ranging from 0.82 to 2.5 cases per 100,000 inhabitants, followed by New Zealand and the United States [1].

The main risk factors for MCC are advanced age (average of 77 years), ultraviolet exposure, lighter skin, male gender, immunosuppression, and MCPyV1 infection. It also stands out clinically as a skin-colored or reddish, firm, asymptomatic, and indolent nodule or plaque, appearing in areas commonly exposed to solar radiation, with the possibility of increasing its size rapidly in weeks or months [1].

As a result, MCC is misdiagnosed due to its somewhat non-specific clinical findings, which can be confused with inflammatory lesions, such as acne and folliculitis, or benign skin tumors [1]. Given its non-specific morphology, dermoscopy and biopsy are essential for confirming its diagnosis. In order to provide early treatment,

innovations in this area are increasingly being highlighted, especially immunotherapy methods [1].

Therefore, this study aims to report the case of an 82-year-old patient diagnosed with metastatic MCC who underwent immunotherapy in order to emphasize the importance of this innovative therapy in the prognosis of patients with this pathology.

2. PRESENTATION OF CASE

Male, 82 years, reports that, after removing lesions compatible with Basal Cell Carcinoma in 2020, a new lesion appeared on his face in the right frontal region, whose immunohistochemical study confirmed MCC, and he underwent exeresis of the tumor.

After five months, he reported more skin lesions in the frontal, occipital, right temporal, left nasal wing and left lower eyelid regions (Image 1). The histopathology (Image 2) showed Squamous Cell Carcinoma in situ in the first lesion, moderately differentiated Invasive Cell Carcinoma in the second, and a malignant round cell ulcerated neoplasm on the scalp.

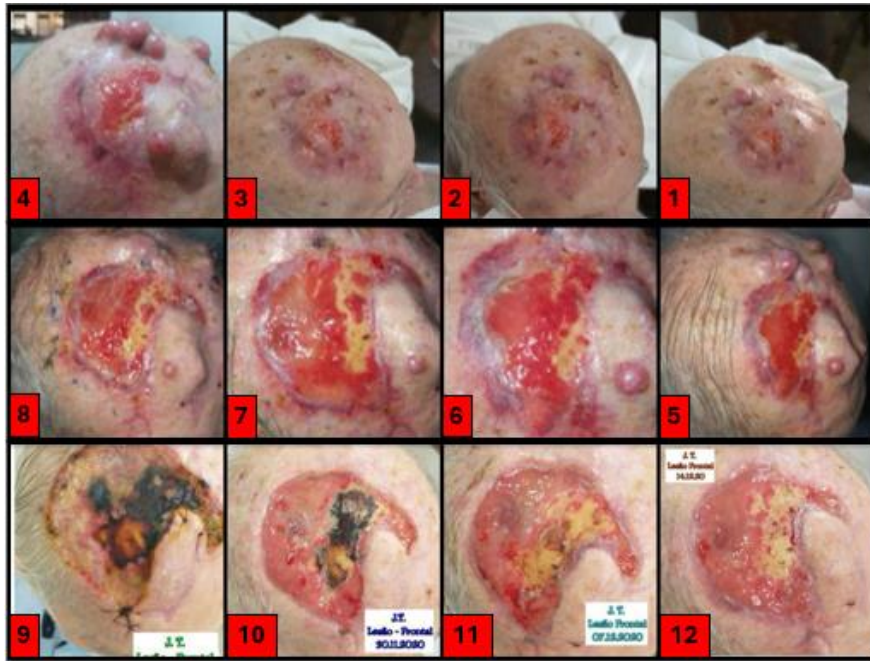


Image 1. Images of the Evolution of the lesions in the patient's frontal region

Source: Authors

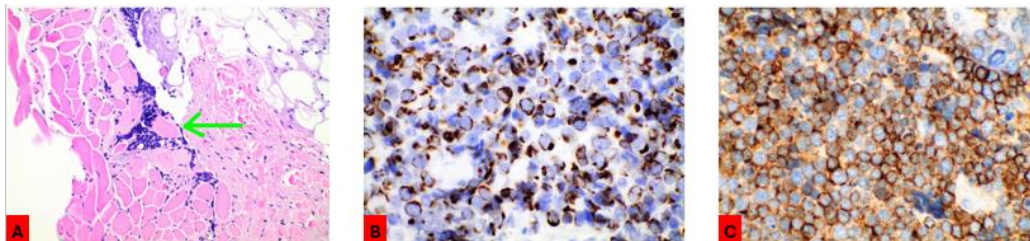


Image 2. Histopathology of the lesion in the right frontal region

A – Infiltration of striated muscle by neoplastic cells.; B – Expression of cytokeratin 20 (standard “dot”) with classic paranuclear pattern of MCC; and C – Expression of CD 56 and synaptophysin, confirm neuroendocrine origin

Source: Authors

He was then referred by the head and neck surgeon to radiotherapy for evaluation of complementary treatment for MCC. In early 2021, due to pain in the thoracic and lumbar regions and being unable to lie down, he was referred to the emergency room for a computed tomography (CT) scan of the abdomen and pelvis with contrast, which showed multiple pleural implant formations and confluent, slightly heterogeneous enhancement, with the largest of them in direct relation to the anterior portion of the diaphragmatic hemidome on the right, measuring 12.0 x 1.8 cm, as well as multiple lymph nodes suggestive of lymphoproliferative disease.

The following day, when the hematologist referred him to two surgeons, a percutaneous

biopsy of an expansive lesion on the right thoracoabdominal wall was requested. At the time, the patient was hospitalized for palliative treatment of the pain and dyspnea and was discharged a few days later with a request for home care.

The immunohistochemical result showed metastatic MCC. Then, JTA was referred to an oncologist, who showed no many therapeutic options except immunotherapy, which, at the time, didn't have much scientific evidence of its efficacy. Immunotherapy was started ten days after the result and was given every 15 days, with an initial dose of 800mg, four ampoules diluted in serum in a continuous infusion pump for 60 minutes, and prophylactic antipyretic and antiallergic drugs given beforehand. After 15

days of the first dose, he went into anaphylactic shock and underwent a RT-PCR test for COVID-19 at the hospital, which was positive.

Chest CT showed sparse ground-glass opacity in both lungs, probably related to an infectious process. An intensive care unit was recommended, which his family did not allow, coinciding with the lack of beds in the unit due to the COVID-19 pandemic. The patient spent seven days in the hospital for observation. Immunotherapy was adjusted to 90 minutes in duration. In April 2021, a new chest CT scan was performed, which showed the disappearance of ground-glass opacities, non-specific micronodules with sparse soft tissue density in the lungs, and calcified micronodules compatible with granulomas in the middle lobe.

On a new abdominal and pelvic CT scan, the pleural effusion disappeared. There was a pleural nodular thickening just diaphragmatic to the right, with mass formation, a reduction in the size of the expansive lesion in the right colon, around 2.3 cm on this scan, which could be residual, as well as a reduction in the subdiaphragmatic, subpatic, retrocruval, mesenteric, and retroperitoneal lymph node masses.

At the 60th dose of immunotherapy, the patient reported no side effects, not impacting his daily routine. JTA monitors the progress of his treatment with imaging tests and needs to undergo immunotherapy throughout his life.

3. RESULTS AND DISCUSSION

Despite its rarity, there has been a growing incidence of MCC, with studies showing a 95% increase in cases of this pathology in the United States between 2000 and 2013, with 2,488 cases recorded in the latter year and an estimated 3,284 cases by 2025, especially with an aging population [1]. In addition, risk factors are also related to this estimate, with emphasis on advanced age, white race, male gender, and exposure to ultraviolet radiation (UVR), especially in the head and neck regions, as was described in this case [1].

In addition, the probable multifactorial etiology of MCC is evident, linked to immunosuppression and damage secondary to exposure to UVR and viral factors. Despite that, its oncogenesis has not yet been fully clarified, except for the elucidation of the participation of the "recently"

discovered merkel cell polyomavirus (MCPyV) [1]. This agent has been identified as a member of the skin microbiota and belongs to the human polyomavirus (HPyV) family, which produces infections with a scarce clinical picture but with a high possibility of expansion when faced with an immunosuppressed organism [2,3].

In 80% of MCC cases, MCPyV is present, while in the remainder there are mutations in the retinoblastoma and p53 proteins, activating the LT MCPyV antigen, which binds to the former and inactivates its role in tumor suppression [1]. This mechanism is predominant in populations with greater exposure to UVR, in association with a significantly increased tumor mutational burden (TMB) in relation to MCPyV positives, characterizing a mutation probably related to this risk factor [3,4].

On the other hand, in patients who are positive for this infection, there is a greater expression of the ST antigen, which binds to Fbxm7 and plays a tumor-suppressing role, accumulating oncogenic proteins [1]. Given the high immunogenicity of both pathophysiological forms, the need for therapies aimed at these mechanisms is confirmed, as was done in this case.

The clinical presentation of MCC, as seen in the case previously described, is most often asymptomatic and non-specific, usually manifesting as a single, firm, red to violet nodular lesion that evolves rapidly. It can also be pleomorphic, plaque-like, skin-colored, or in the form of subcutaneous nodules, and, in advanced stages, ulcerations or crusts appear on the lesions [5]. On physical examination, dermoscopy shows a variation between areas of vascularization with a variable or monomorphic morphology, with a generalized erythematous appearance, as well as pinkish areas with white linear or structureless regions [1].

In terms of diagnosis, which is also confirmed by histopathology, there is dermal proliferation in nests or layers with small, round, uniform blue undifferentiated cells with scarce cytoplasm, as well as a high mitotic rate, while immunophenotyping shows positivity for CK20, chromogranin A, synaptophysin, and negativity for TTF-1 [6,7].

Surgical treatment with excision of the lesion to obtain histologically free margins is recommended for resection of the primary tumor

in patients with localized disease and some cases of metastatic disease [8,9]. Immunotherapy, also used in this patient's case, despite its high cost, is making progress in the treatment of MCC, not only in terms of patient survival but also in terms of a better quality of life, especially in terms of psychological well-being and physical performance, as well as having fewer adverse effects compared to radiotherapy [10]. The effects of immunotherapy on survival make it even more important in cases of MCC in elderly patients, such as this case.

Avelumab (an anti-PD-L1 monoclonal antibody) was the first approved for use by the Food and Drug Administration, with a response rate of 32 to 56%, of which 10 to 15% showed complete remission, as occurred in the present case [4]. In addition, other options like pembrolizumab (a humanized IgG4 anti-PD-1 antibody) and nivolumab (a human IgG4 antibody against PD-1) are emerging in the same line of research. For this reason, as the systemic treatment of this class of substances has shown promising results, the National Comprehensive Cancer Network (NCCN) guidelines already recommend them for locally advanced metastatic or recurrent MCC [4].

4. CONCLUSION

Considering the difficulty in early diagnosis and, mainly, given the complexity of treating metastatic MCC, this case report illustrates the emerging role of immunotherapy as a promising option in the face of this challenging condition, particularly in the elderly and immunocompromised. Therefore, the results developed after immunotherapy treatment suggest the need for greater monitoring and research into its long-term effectiveness in the treatment of MCC, in addition to the search for validation of an approach that provides the patient with a better prognosis and greater quality of life.

DISCLAIMER (ARTIFICIAL INTELLIGENCE)

Authors hereby declares that NO generative AI technologies such as Large Language Models (ChatGPT, COPILOT, etc) and text-to-image generators have been used during writing or editing of this manuscript.

CONSENT

The authors report that they have the patient's consent, which is available upon request.

ETHICAL APPROVAL

As per international standards or university standards written ethical approval has been collected and preserved by the author(s).

ACKNOWLEDGEMENTS

We would like to express our special thanks to the Olinda Medical School – FMO staff.

COMPETING INTERESTS

Authors have declared that no competing interests exist.

REFERENCES

1. Marie-Léa Gauci, Cynthia Aristei, Jurgen C Becker, Claus Garbe, Céleste Lebbé, et al. Diagnosis and treatment of merkel cell carcinoma: European consensus-based interdisciplinary guideline – update 2022 On behalf of the European Dermatology Forum (EDF), the European Association of Dermato-Oncology (EADO) and the European Organization for Research and Treatment of Cancer (EORTC); 2022. Open Access Published: June 19, 2022. DOI: <https://doi.org/10.1016/j.ejca.2022.03.043>
2. Arora R, Chang Y, Moore PS. MCV and Merkel cell carcinoma: A molecular success story. *Curr Opin Virol.* 2012;2(4): 489–498.
3. Dalianis T, Hirsch HH. Human polyomaviruses in disease and cancer. *Virology.* 2013;437(2):63–72.
4. Urs Dietmar Achim Müller-Richter, Anja Gesierich, Alexander Christian Kübler, Stefan Hartmann. Roman Camillus Brands 3 5. Merkel Cell Carcinoma of the Head and Neck: Recommendations for Diagnostics and Treatment. PMID: 28762116 PMCID: PMC5596053 DOI: 10.1245/s10434-017-5993-1
5. Yun Xue, Manisha Thakuria. Merkel Cell Carcinoma Review. *Hematol Oncol Clin North Am.* 2019 Feb;33(1):39-52. DOI: 10.1016/j.hoc.2018.08.002.
6. Huber GF. Modern management of merkel cell carcinoma. *Curr Opin Otolaryngol Head Neck Surg.* 2014;22(2):109–115.
7. Ramahi E, Choi J, Fuller CD, Eng TY. Merkel cell carcinoma. *Am J Clin Oncol.* 2013;36(3):299–309.

8. Bichakjian CK, Olencki T, Aasi SZ, Alam M, Andersen JS, Blitzblau R, Bowen GM, Contreras CM, Daniels GA, Decker R et al. Merkel cell carcinoma, version 1.2018, NCCN Clinical Practice Guidelines in Oncology. J. Natl. Compr. Cancer Netw. 2018;16:742–774.
9. Mehran Behruj Yusuf , Grant McKenzie, Abbas Rattani, Paul Tennant, Jeffrey Bumpous, Donald Miller, Neal Dunlap. Merkel cell carcinoma of the head and neck: Epidemiology, pathogenesis, current state of treatment and future directions. PMID: 34298720 PMID: PMC8305628 DOI: 10.3390/cancers13143506
10. Lambert J, Marrel A, D'Angelo SP, Burgess MA, Chmielowski B, Fazio N, Gambichler T, Grob JJ, Lebbé C, Robert C et al. Patient experiences with avelumab in treatment-naïve metastatic merkel cell carcinoma: Longitudinal qualitative interview findings from javelin merkel 200, a Registrational Clinical Trial. Patient-Patient-Cent. Outcomes Res. 2020; 13:457–467.

Disclaimer/Publisher's Note: The statements, opinions and data contained in all publications are solely those of the individual author(s) and contributor(s) and not of the publisher and/or the editor(s). This publisher and/or the editor(s) disclaim responsibility for any injury to people or property resulting from any ideas, methods, instructions or products referred to in the content.

© Copyright (2024): Author(s). The licensee is the journal publisher. This is an Open Access article distributed under the terms of the Creative Commons Attribution License (<http://creativecommons.org/licenses/by/4.0>), which permits unrestricted use, distribution, and reproduction in any medium, provided the original work is properly cited.

Peer-review history:

The peer review history for this paper can be accessed here:
<https://www.sdiarticle5.com/review-history/122570>