



Cerebral Venous Thrombosis: Study of 12 Cases from Southern Brazil

Otto Jesus Hernandez Fustes^{1,2*}, Carlos Arteaga Rodriguez³ and Georgette Mouchaileh E. Ferreira²

¹*InNeuro, Curitiba, Brazil.*

²*Neurology Service, Hospital das Nações, Curitiba, Brazil.*

³*Positivo University, Medicine Department, Curitiba, Brazil.*

Authors' contributions

This work was carried out in collaboration among all authors. All authors read and approved the final manuscript.

Article Information

Editor(s):

(1) Dr. Takashi Ikeno, National Center of Neurology and Psychiatry, Japan.

Reviewers:

(1) Belete Negese, Debre Berhan University, Ethiopia.

(2) Mrs. Sarika Sukesh Nair, MGM New Bombay College of Nursing, India.

Complete Peer review History: <http://www.sdiarticle4.com/review-history/64951>

Short Communication

Received 20 November 2020

Accepted 25 January 2021

Published 17 February 2021

ABSTRACT

Cerebral venous thrombosis (CVT) is a pathology that affects the cerebral venous sinuses causing an ischemic and/or hemorrhagic brain, but, contrary to the arterial cerebral vascular accident, has a clinical presentation with varied signs and symptoms that are difficult to diagnose in its initial phase. Objective: To present the clinical findings of twelve cases of CVT. Materials and methods: We reviewed the charts of patients admitted with a diagnosis of CVT. Results: We describe 8 females and 4 males, with mean age of 30 years. The most common signs and symptoms were: headache (89%), seizure (55.5%), cranial nerve palsy (44%) and hemiparesis (33%). All patients had diagnoses confirmed by nuclear magnetic resonance of the skull. The risk factors found were the use of oral and puerperium contraceptives. All patients were treated with oral anticoagulant, with no death reported in this series. Conclusion: Venous sinus thrombosis is an uncommon disease that requires a high index of suspected diagnosis by the medical team. The mortality rate is low and the treatment is usually effective.

*Corresponding author: E-mail: otto.fustes@hc.ufpr.br;

Keywords: *Thrombosis; cerebral venous sinus; stroke.*

1. INTRODUCTION

Cerebral venous thrombosis (CVT) is a pathological process characterized by the formation of thrombi in the cerebral venous system leading to an ischemic and / or hemorrhagic infarction of the affected area. The clinical presentation of CVT is varied, onset may be acute, subacute or chronic, and headache is usually a symptom present.

The first anatomical and clinical descriptions were made by Morgagni in 1760 and Ribes in 1825, later Gowers in 1888 related it to pregnancy and the puerperium. [1] Considered an unusual pathology, the initial reports were based on autopsy series. In recent years, with the advancement of imaging techniques, the identification of a greater number of patients was possible, but the disease continues without a defined etiology, some risk factors and few epidemiological data are known. Some studies show that the disease equally affects both sexes and a slight predominance of the female sex, in the age group between 20 and 35 years of age, associated with pregnancy, the puerperium and the use of contraceptives. [2,3,4] Other causes described are: trauma, inflammatory diseases and infection of the central nervous system. [4,5] Our objective is to describe the clinical manifestations and etiology of twelve patients from southern Brazil with cerebral venous thrombosis.

2. MATERIALS AND METHODS

An observational, retrospective and descriptive study of the patients with CVT admitted to a University Hospital in Curitiba, southern Brazil, was carried out for three years, all of them had the cerebrovascular disease protocol from which demographic data, clinical history, physical examination, laboratory examinations, radiological examinations, Rankin Scale and treatment used were obtained. Data are presented in percentages and arithmetic mean.

3. RESULTS

The records of twelve patients, 8 women and 4 men aged between 14 and 51 years, and an average of 31 years were reviewed. The most common signs and symptoms that appeared in order of frequency were headache, seizures,

cranial nerve paralysis, hemiparesis, and mixed aphasia. Only one patient presented a comatose state. As for the vessels involved, in order of frequency they were: transverse, superior sagittal, sigmoid, cavernous and rectum (Table 1).

Laboratory tests included: blood count, coagulogram, sodium, potassium, urea, creatinine, calcium, magnesium, erythrocyte sedimentation rate, rheumatoid factor, tests for thyroid function and liver function, protein C and S, antithrombin III, factor Leiden V and anticardiolipin antibody. In two cases we found criteria for thrombophilia. All the patients underwent a brain CT and later an MRI, and this last examination was positive for the diagnosis (Fig. 1). Of the investigated patients, five presented an etiological diagnosis (Table 1). The treatment used for all patients was heparin, with concomitant initiation of oral anticoagulant. The oral anticoagulant dose was controlled by prothrombin activation time. Only two patients remained with sequelae. There were no deaths recorded in this series.

4. DISCUSSION

Predisposing factors can be identified in up to 75% of patients with this diagnosis, according to some authors. [2,6] In our study, the etiological factor was defined in 55.5% of the patients, three cases of the puerperium, one case of contraceptive use and one case of infection of the central nervous system.

The most affected venous sinuses are the superior sagittal sinus and the lateral sinus, being that in 33% of cases there is more than one attacked venous sinus. [6,7,8,9] In approximately 75% of cases, they have epileptic seizures and headaches. In 20 to 40% of cases, patients present with papilledema and visual acuity disorders, reminiscent of intracranial hypertension syndrome. A third group presented motor deficits associated with epileptic seizures and the fourth group presented with painful ophthalmoplegia. Headache is generally a symptom present in 70% to 90% of cases. [3,7] Seizures can be present in up to 40% of cases, generally partial ones are more frequent than generalized ones, and are a consequence of the areas of cerebral infarction. [3,10]

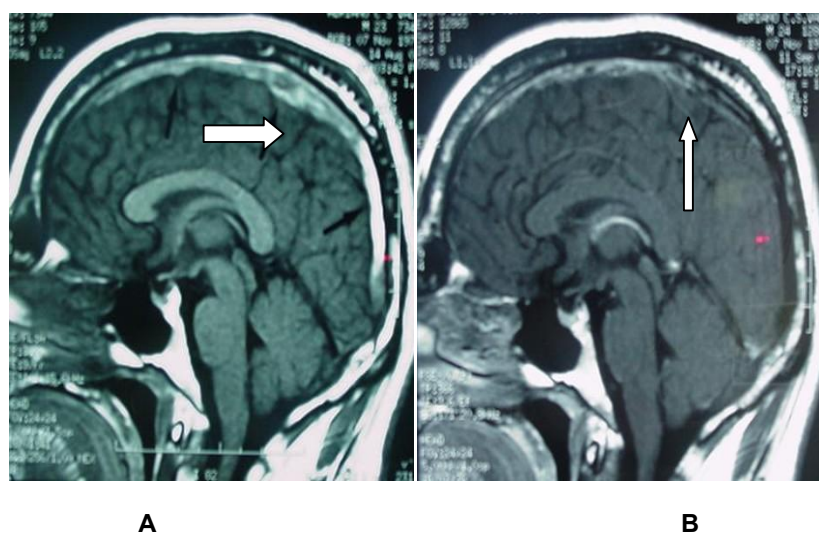


Fig. 1. Brain MRI showing thrombosis of the superior sagittal sinus (A) and partial recanalization after treatment (B)

Table 1. Clinical-demographic characteristics

Gender/ Age in years	Symptomatology	Sinus occluded	Etiology	Sequelae
Female/36	Headache, seizure	Transverse	No determined	No
Female/26	Seizures	Transverse, sigmoid	Puerperium	No
Male/24	Headache	Sagittal, transverse, sigmoid	No determined	No
Female/31	Headache, seizures	Sagittal, transverse	Puerperium/ Antiphospholipid syndrome	Decreased visual acuity
Female/23	Headache, coma, aphasia, hemiparesis, ophthalmoparesis	Transverse, sigmoid, rectum	Contraceptive	Aphasia, hemiparesis, ophthalmoparesis
Female/29	Headache	Cavernous, sagittal	No determined	No
Male/14	Headache, seizure	Sagittal	Brain abscess	No
Female/36	Headache, hemiparesis	Sagittal	Puerperium	No
Male/51	Headache, seizures, hemiparesis, ophthalmoparesis	Transverse	No determined	Epilepsy
Male/26	Headache, ophthalmoparesis	Sagittal, transverse	Thrombophilia	No
Female/37	Headache	Transverse	Not determined	No
Female/28	Headache	Transverse, sigmoid	Contraceptive	No

The investigation must be based to establish the diagnosis and the etiology, hematological, metabolic, inflammatory, infectious, endocrine and coagulation disorders must be investigated. [6] Magnetic resonance imaging with venography has been the examination of choice for the diagnosis and monitoring of cerebral venous sinus thrombosis. [2,5,7]

As it is a rare pathology, there are few therapeutic trials for cerebral venous sinus thrombosis. Treatment modalities include heparin, thrombolysis, and oral anticoagulants. [11,12]

The prognosis for cerebral venous sinus thrombosis is good. Between 57% and 86% of patients survive with complete recovery of the condition [4,7,13], this result being observed in our series of patients, with recovery of 78% of patients. Mortality reaches rates of approximately 5% to 10% [2,7] and recurrence stands at 2.8 per 100 cases. In our patients, recurrence was observed in one patient, with involvement of the same vessel. The prognosis worsens when the patient presents risk factors for the disease that are not potentially curable. TVI remains an important differential diagnosis in patients with headache, seizures, and other neurologic deficits. [13,14,15]

5. CONCLUSION

There are very few studies with good epidemiological quality, particularly in developing countries, where the incidence of TVI seems to be higher, probably reflecting high pregnancy rates and high prevalence of infections and nutritional deficits, so it must be remembered to be properly investigated. and diagnosed, since when properly treated it has a low mortality rate.

CONSENT

As per international standard or university standard, Patients' written consent has been collected and preserved by the authors.

ETHICAL APPROVAL

It is not applicable.

COMPETING INTERESTS

Authors have declared that no competing interests exist.

REFERENCES

1. Imai WK, Everhart FR, Sanders JM. Cerebral venous sinus thrombosis: Report of a case and review of the literature. *Pediatrics*. 1982;70(6):965-970.
2. Al Hashmi K, Al Wahaibi K, Al-Khabori M, Al Lamki S. Characteristics and Outcomes of Patients with Cerebral Venous Sinus Thrombosis. *Oman Med J*. 2019; 34(5):434-437. DOI: 10.5001/omj.2019.79
3. Wasay M, Kaul S, Menon B, Dai AI, Saadatia M, Malik A, et al. Asian study of cerebral venous thrombosis. *J Stroke Cerebrovasc Dis*. 2019;28(10):104247. DOI:10.1016/j.jstrokecerebrovasdis.2019.06.005
4. Saposnik G, Barinagarrementeria F, Brown RD, Bushnell CD, Cucchiara B, Cushman M, deVeber G, Ferro JM, Tsai FY, on behalf of the American Heart Association Stroke Council and the Council on Epidemiology and Prevention. Diagnosis and management of cerebral venous thrombosis: a statement for healthcare professionals from the American Heart Association/American Stroke Association. *Stroke*. 2011;42:1158–1192. Available:https://doi.org/10.1161/STR.0b013e31820a8364
5. Ghoneim A, Straiton J, Pollard C, Macdonald K, Jampana R. Imaging of cerebral venous thrombosis. *Clin Radiol*. 2020;75(4):254-264. DOI: 10.1016/j.crad.2019.12.009
6. Villringer A, Mehraein S, Einhäupl KM. Pathophysiological aspects of cerebral sinus venous thrombosis. *J Neuroradiol*. 1994;21:72-80.
7. Shahid R, Zafar A, Nazish S, et al. Etiologic and clinical features of cerebral venous sinus thrombosis in Saudi Arabia. *J Neurosci Rural Pract*. 2019;10(2):278–282. DOI: 10.4103/jnpr.jnpr_305_18
8. Dmytriw AA, Song JSA, Yu E, et al. Cerebral venous thrombosis: state of the art diagnosis and management. *Neuroradiology*. 2018;60:669–685. Available:https://doi.org/10.1007/s00234-018-2032-2
9. Kalita J, Singh VK, Jain N, Misra UK, Kumar S. Cerebral venous sinus thrombosis score and its correlation with clinical and MRI findings. *J Stroke Cerebrovasc Dis*. 2019;28(11):104324.

- DOI:10.1016/j.jstrokecerebrovasdis.2019.104324
10. Hao Lia, Liqian Cuia, Ziyi Chen, Yue Chen. Risk factors for early-onset seizures in patients with cerebral venous sinus thrombosis: A meta-analysis of observational studies. *Seizure: European Journal of Epilepsy*. 2019;72:33–39. Available:https://doi.org/10.1016/j.seizure.2019.09.006
 11. Einhäupl K, Stam J, Bousser MG, De Bruijn SF, Ferro JM, Martinelli I, Masuhr F. European Federation of Neurological Societies. EFNS guideline on the treatment of cerebral venous and sinus thrombosis in adult patients. *Eur J Neurol*. 2010;17(10):1229-35. DOI: 10.1111/j.1468-1331.2010.03011.x.
 12. Ferro JM, Aguiar de Sousa D. Cerebral venous thrombosis: An update. *Current Neurology and Neuroscience Reports*. 2019; 19: 74. Available:https://doi.org/10.1007/s11910-019-0988-x
 13. Guenther G, Arauz A. Cerebral venous thrombosis: A diagnostic and treatment update. *Neurología*. 2011;26:488-498. DOI:10.1016/j.nrl.2010.09.013
 14. Martínez-Martínez M, Cazorla-García R, Rodríguez de Antonio LA, Martínez-Sánchez P, Fuentes B, Díez-Tejedor E. Hypercoagulability and ischemic stroke in young patients. *Neurología*. 2010;25:343-348. DOI:10.1016/j.nrl.2009.01.001
 15. Silvis S, De Sousa, D, Ferro J, et al. Cerebral venous thrombosis. *Nat Rev Neurol* 2017;13:555–565. Available:https://doi.org/10.1038/nrneurol.2017.104

© 2021 Fustes et al.; This is an Open Access article distributed under the terms of the Creative Commons Attribution License (<http://creativecommons.org/licenses/by/4.0>), which permits unrestricted use, distribution, and reproduction in any medium, provided the original work is properly cited.

Peer-review history:

*The peer review history for this paper can be accessed here:
<http://www.sdiarticle4.com/review-history/64951>*