



Amniotic Band Sequence Syndrome – A Rare Disorder

Priyanka Singh^{1*}, Neema Acharya¹, Rishabh Gupta² and Rajesh Kumar Vasam³

¹Department of Obstetrics and Gynecology, Jawaharlal Nehru Medical College, Datta Meghe Institute of Medical Sciences, Sawangi, Wardha, India.

²Department of Radiology, Jawaharlal Nehru Medical College, Datta Meghe Institute of Medical Sciences, Sawangi, Wardha, India.

³Jawaharlal Nehru Medical College, Datta Meghe Institute of Medical Sciences, India.

Authors' contributions

This work was carried out in collaboration among all authors. All authors read and approved the final manuscript.

Article Information

DOI: 10.9734/JPRI/2021/v33i46A32833

Editor(s):

(1) Dr. Prem K. Ramasamy, Brandeis University, USA.

Reviewers:

(1) Sivalingam Nalliah, International Medical University, Malaysia.

(2) Michail Diakosavvas, Alexandra Hospital, National and Kapodistrian University of Athens, Greece.

Complete Peer review History: <https://www.sdiarticle4.com/review-history/73477>

Case Report

Received 10 July 2021

Accepted 09 September 2021

Published 11 October 2021

ABSTRACT

Amniotic bands sequence is a inherited diseases distinguished by craniofacial, body wall, and limb oddities that may be in relation with foetal-placental fibrous bands. Its pervasiveness has been delineated to range from 0.19 to 8.1 per 10 000 births [1]. It is a customary state prospectively alike with a variety of different confinements' disability. The deformities arise in the wake of the pompous bodily part have formed usually in early evolution. The required cause of amniotic disruption complex is undisclosed .The three most usual decorative design are constriction ring syndrome signaled by one or more limbs being high-flown; the limb-body- wall complex; and amniotic band syndrome characterized by abnormalities of the head and face (craniofacial abnormalities), inadequacies of the brain and genuine deformation of the appendages [2].

The condition in few cases might be considered prior to nativity (ante partum), unlikely to change upon the sequels of explicit detailed imaging practices, like fetal USG, which may give away the feature inadequacies [3].

Here we present a case of pregnant woman admitted in our Obstetrics and gynecological department with her ultrasonography report indicative of amniotic band and further discussed about antenatal diagnosis, diagnostic and therapeutic approach, prognosis and genetic counselling of amniotic disruption complex.

Keywords: Amniotic band sequence; abnormalities; ultrasonography; defects; organs.

1. INTRODUCTION

Amniotic disruption complex is a troupe of fetal impairments that are related with tendons that twist together copious fetal parts in uterus. Amniotic band sequence develops from in utero entrapment of fetal parts by fibrous bands, which instigate a collection of deformities that can act on multiple organ systems. There is typically an asymmetric issuance of these defects; the most typical exemplifications involve limb deformities. The root of amniotic band sequence is obscure and has been put down to both intrinsic and extrinsic elements. The extrinsic theory for the evolution of amniotic disruption complex is that strands of tissue set apart out of the inmost surface (amnion) of the amniotic sac [4].

On the report of this speculation, constriction ring syndrome transpired while the inmost surface (amnion) of the water bag blowout, exhibiting the fetus to strands of tendon that may awash in the amniotic fluid or endure partly connected to the water bag. These straps of tissue can disorganized the standard evolution of a embryo. The bands of tissue can constrict the fingers, toes, arms, legs and other parts of the evolving fetus (Singh and Gorla, 2021).

The intrinsic theory imputes the evolution of constriction ring syndrome to recompensed blood as a subordinate upshot of the recompensed blood flow [5].

The principle impetus of this report is to know the gravity and type of oddities for pinpointing and approach of obstetrician for tonic and estimate for the site of delivery.

2. CASE REPORT

A 25-year-old un-booked Primigravida with 27 weeks gestational age came to casualty in emergency hours with history of preterm labor pains. She also gave history of white discharge present since, 1 day. All her antenatal care visits record and investigation were in normal limits except her ultrasonography report showing thick intrauterine septum.

The senior resident of emergency department examined her with this history and hence she was admitted in obstetric ward. On admission her general condition- fair, afebrile, PR-98 bpm and BP-120/80 mm hg. There was no pallor and oedema present. On per abdomen fundal height was 28 weeks size, there was single fetus with variable presentation. The blood investigation's were carried out which revealed hemoglobin of 10.4 gm/dl, total leucocyte count-14,100/cu-mm, total platelet count-2.67 lacs/cu mm. In view of above unearthing oral antibiotics, tocolysis and vaginal pessary were started.

The ultrasonography was carried out next day to check for liquor amnii, cervical canal and any suspected adnexal or uterine pathology/abnormality (uterine septum).The ultrasonography report revealed amniotic band. The report was explained to both patients and her relative. Counselling was done. patient got discharged after 2-3 days after managing her conservatively for preterm labour pains.

The patient visited us at 8 months of gestation with pre term labor pains. Gestation was mediocre, accompanied by the anomaly that the birth of 2 weeks premature female child by vaginal delivery and weigh 2 kg. On health check of the beneath extremities disclosed residues of a mild amniotic band indentation tracked down somewhat remote to the tibial tuberosity on the right leg there. Physical examination of the right foot revealed a forefoot varus and fixed equines position. Clubfoot deformity here was firm accompanied by a drop scope of motion at all joints entailed. With the abet of USG, a prenatal screening of amniotic band series can be made by ensuing critical examination for reduction in size or extent for fetal manoeuvre. Pertinent intervention can abolish latent limb-menacing constrictions and furnish boosted welfare and wellbeing for these patients.

3. DISCUSSION

A comprehensive ultrasound scanning is endorsed to pick out the expanse of anomalies. Medical termination of pregnancy should be

talked through with all patients in whom a foetal anomaly is encountered and confabbed for future obstacles. Ultrasonography and imaging studies to be done at periodic interlude months. Antenatal monitoring to be executed if growth restriction is present.

A study carried out by Sinha et al., that a tightening was restricted to the remote skin tag and partial bands atop the other limbs lead us to

accredit the inadequacy to amniotic bands. Distinct diagnosis of amniotic band inadequacy may incorporate a disorders of multiple benign annulated skin creases. This is an autosomal governing trait and these compressions flatter less notable as the child fill out [6].

It requires great effort to visualize the amniotic bands in the first trimester also more difficult is to identify these bands if they are present in the

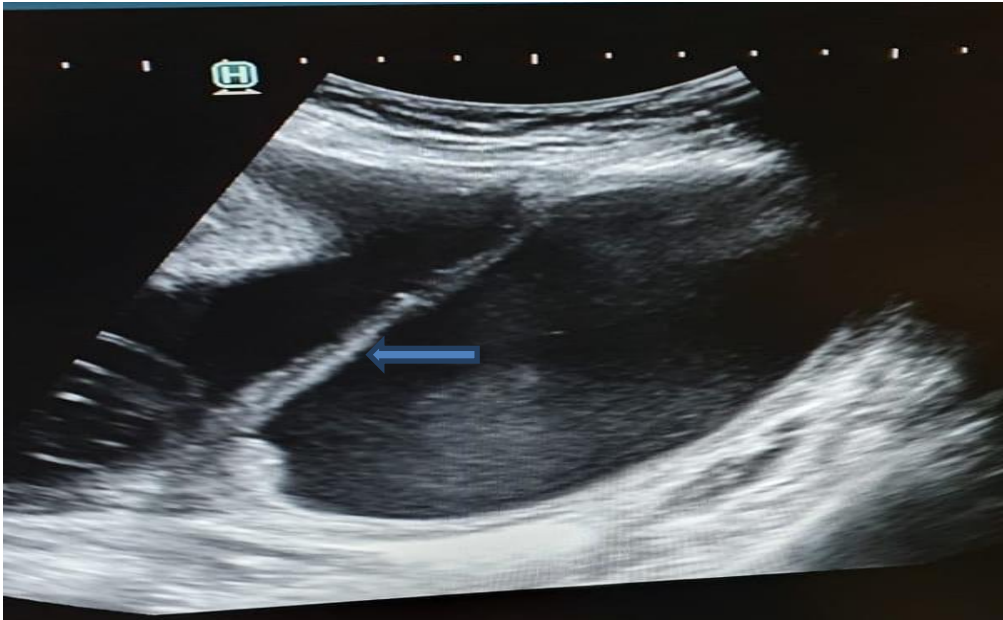


Fig. 1. The ultrasonography report revealed amniotic band with thick intrauterine septum

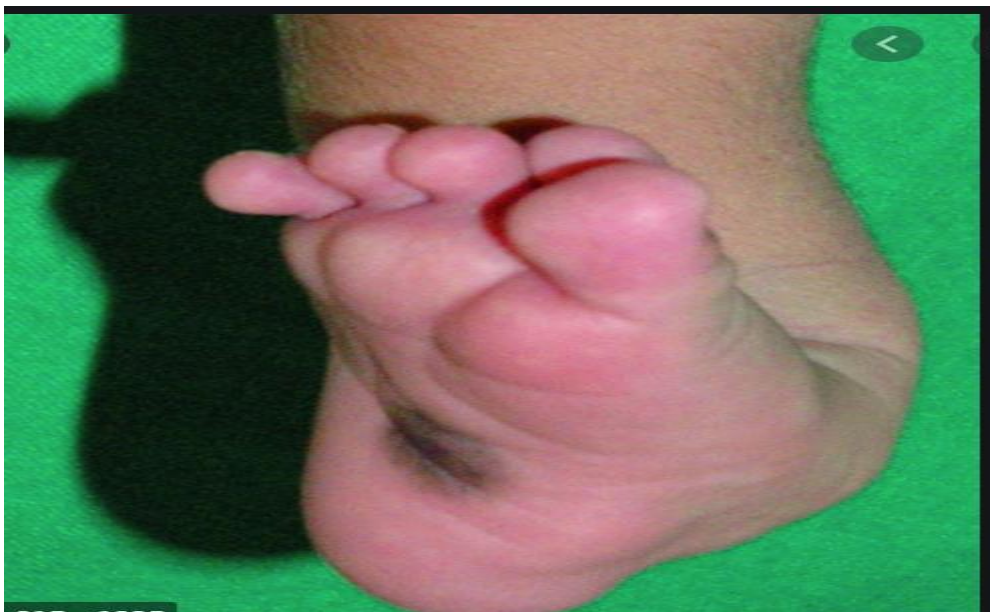

Fig. 2. The infant was diagnosed with amniotic band syndrome with talipes equinovarus deformity of her left foot

extremities. The ultrasonographic analysis concedes for the discernment of amniotic band syndrome antenatally by envisaging of amniotic sheets or bands connected to the embryo. It is difficult to contemplate the amniotic bands in the first three months, and it is more difficult to spot these bands if these are present in the edges. Nevertheless, in the second and third three months of gestation, it is moderately effortless to disclosed the vital deformities of amniotic band syndrome by its attribute marks and cutback motion [7].

Congenital ring constriction, amniotic band disruption complex, or congenital transverse inadequacy are several synonyms defining this deformative disorder, manifesting besides its clinical irregularities, or the precarious surrounding and its etiology. The invasive treatment actually tries only to the subsequent to upshots of the intrauterine pH, upto antepartum pinpointing come after by in utero section will be perfected in the study Pouef B et al. [8]

The inquiry conveyed by Keswani et al., the administration of this syndrome embraces early spotting by ongoing USG perusal in gestation and intrauterine intercessions' course of action for continuing remote vascularity. The practices of foetal intercessions' take in open foetal surgery, "Fetendo" foetal incision and foetal image-guided surgery (FIGS-IT). Expose foetal surgery, the mother is sedated, an incision is obliged in the beneath abdomen to bare the uterus, a special stapling tool is used to bare the uterus to stave off bleeding, the invasive mend of the foetus is completed and the uterus following this maternal abdominal partitions are slammed, and the mother awaken conscious [9].

4. CONCLUSION

Amniotic band sequence syndrome is one detecting amniotic band syndrome feasibly challenging, for the most part prenatally. Follow-up, ultrasound, and intervention and consulting can aid one step better in maternal and fetal outcome.

Postnatal management take in thorough physical exam, and if required, imaging inquiries to distinctly recount the scope of amniotic band syndrome. Despite the fact that, fetoscopy intervention may assist in farther management. Look for intensive negotiation in the trailing of an error-free and precise pinpointing and genetic assisting.

CONSENT AND ETHICAL APPROVAL

As per international standard or university standard guideline patient's written consent and ethical approval has been collected and preserved by the authors.

ACKNOWLEDGEMENT

We thank all the participants who have contributed in this study.

COMPETING INTERESTS

Authors have declared that no competing interests exist.

REFERENCES

1. An update on amniotic bands sequence. Arch Argent Pediatr [Internet]. 2018; 116(3). [Cited 2020 May 5]. Available:<http://www.sap.org.ar/docs/publicaciones/archivosarg/2018/v116n3a17e.pdf>
2. Amniotic Band Syndrome [Internet]. NORD (National Organization for Rare Disorders). [Cited 2020 May 5]. Available:<https://rarediseases.org/rare-diseases/amniotic-band-syndrome/>
3. Reddy UM, Filly RA, Copel JA. Prenatal Imaging: Ultrasonography and Magnetic Resonance Imaging. Obstet Gynecol. 2008;112(1):145–57.
4. Gandhi M, Rac MWF, McKinney J. Amniotic Band Sequence. Am J Obstet Gynecol. 2019;221(6):B5–6.
5. Cignini P, Giorlandino C, Padula F, Dugo N, Cafà EV, Spata A. Epidemiology and risk factors of amniotic band syndrome, or ADAM sequence. J Prenat Med. 2012;6(4):59–63.
6. Sinha R, Singh B, Kiran Y, Singh D, Raman TR. Amniotic Band Disruption Sequence. Med J Armed Forces India. 2009; 65(3):274–5.
7. Amniotic Band Syndrome | Johns Hopkins Medicine [Internet]. [Cited 2021 May 12]. Available:<https://www.hopkinsmedicine.org/health/conditions-and-diseases/amniotic-band-syndrome>

8. Poeuf B, Samson P, Magalon G. [Amniotic band syndrome]. Chir Main. 2008;27 Suppl 1:S136-147. limb salvage: Fetoscopic release of amniotic bands for threatened limb amputation. J Pediatr Surg. 2003;38:848–51.
9. Keswani S, Johnson M, Adzick N, Hori S, Howell L, Wilson R, et al. In utero

© 2021 Singh et al.; This is an Open Access article distributed under the terms of the Creative Commons Attribution License (<http://creativecommons.org/licenses/by/4.0>), which permits unrestricted use, distribution, and reproduction in any medium, provided the original work is properly cited.

Peer-review history:

*The peer review history for this paper can be accessed here:
<https://www.sdiarticle4.com/review-history/73477>*