



Sonographic Evaluation of Subscapularis Tendon Tears with Surgical Correlation

Qian Dong^{1*}, Jon A. Jacobson², David A. Jamadar³, Gandikota Girish⁴,
Yoav Morag⁵, Catherine J. Brandon⁶ and David P. Fessell⁷

¹Division of Musculoskeletal Radiology, Department of Radiology, University of Michigan Health System, 1500 E. Medical Center Drive, Ann Arbor, MI 48109-5326, US State.

Authors' contributions

This work was carried out in collaboration between all authors. Authors QD, JAJ performed the study concepts/study design or data acquisition or data analysis/interpretation. Author QD performed the manuscript drafting work and authors QD, JAJ, DAJ performed the whole manuscript editing work. All authors manuscript revision for important intellectual content. Authors DAJ, GG, YM, CJB, DP complete the literature research. All authors read and approved the final manuscript

Article Information

DOI:10.9734/BJMMR/2014/14500

Editor(s):

(1) Masahiro Hasegawa, Department of Orthopaedic Surgery, Mie University Graduate School of Medicine, 2-174 Edobashi, Tsu City, Mie, 514-8507, Japan.

Reviewers:

(1) Filon Agathangelidis, 1st Orthopaedic Department, Aristotle University of Thessaloniki, Greece.
(2) Guilherme Moura da Cunha, Clínica de Diagnóstico por Imagem – CDPI Av. Ataulfo de Paiva, 699, Leblon, Rio de Janeiro, Brazil.

Complete Peer review History: <http://www.sciencedomain.org/review-history.php?iid=719&id=12&aid=6965>

Original Research Article

Received 1st October 2014
Accepted 1st November 2014
Published 15th November 2014

ABSTRACT

Aims: The purpose of this study was to evaluate the ability of ultrasound in detecting subscapularis tendon pathology with operative correlation.

Methodology: A retrospective study was conducted on 86 patients who had shoulder ultrasound prior to surgical repair from January 2006 to August 2008. All sonographic examinations and surgical reports were reviewed. Sonographic evaluation of subscapularis tendon, including normal, tendinosis, partial thickness tear, full thickness tear, and complete tear were correlated to operative reports.

Results: Of the 86 patients, 19 patients had surgically proven abnormal subscapularis tendons. There was 100% ultrasound concordance in tendinosis (n = 1), 100 % ultrasound concordance in partial thickness tears (n =3), 88 % ultrasound concordance in full thickness tears (n = 8), 57 % ultrasound concordance in complete tears (n = 7). Overall, there was 79% ultrasound concordance

*Corresponding author: Email: bingch@umich.edu;

in diagnosing subscapularis tendon pathology when surgery is used as a gold standard.

Conclusion: Ultrasound is useful in the evaluation of the subscapularis tendon. The sonographic findings of tendinosis and partial thickness tears correlate best with surgery. However, ultrasound may underestimate complete tears.

Keywords: Rotator cuff; subscapularis; sonography; shoulder; rotator cuff tear; tendinosis.

1. INTRODUCTION

As the sole anterior component of the rotator cuff, the subscapularis muscle and tendon provide active internal rotation and contribute to the dynamic anterior stability of the glenohumeral joint [1-3]. While rotator cuff tears are a common cause of shoulder pain and dysfunction, tears of the subscapularis tendon occur far less frequently than posterosuperior rotator cuff tears that usually involve the supraspinatus and infraspinatus tendons [4-6]. Subscapularis tendon tears may present as isolated or combined with supraspinatus and/or infraspinatus tendon tears. Isolated subscapularis tears are rare, and typically a result of traumatic injury [7,8]. Without treatment, subscapularis tears may lead to pain, loss of function, and weakness [4,9]. Successful detection and quantification of subscapularis pathology provide useful information to guide treatment decisions such as surgical indications and surgical approach, and perhaps most importantly affect prognosis [10,11].

With considerable development over the past decades, ultrasound has become a powerful technique in evaluating rotator cuff pathology. Previous studies have shown that ultrasound (US) and magnetic resonance imaging (MRI) have comparable degrees of accuracy for diagnosing and measuring rotator cuff tears [12,13]. However, advantages of high-resolution ultrasound allow low-cost and convenient imaging, as well as ease of contralateral comparison and the ability of dynamic evaluation.

There is a relative paucity of literature on ultrasound evaluation of subscapularis tendon pathology [14,15]. The purpose of this study was to evaluate the ability of ultrasound in detecting subscapularis tendon pathology with operative correlation.

2. MATERIALS AND METHODS

Institutional review board approval was obtained before commencing this retrospective study with informed consent waived. A search at our institution revealed 86 consecutive patients who

underwent surgical repair for rotator cuff between January 2006 and August 2008. Of these 86 patients, 19 with surgically abnormal subscapularis tendons were classified as tendinosis, partial thickness tear, full thickness tear, and complete tear. The preoperative ultrasound examinations of these 19 patients were reviewed and compared to operative findings by a fellowship-trained musculoskeletal radiologist with 5 years of musculoskeletal ultrasound experience. When there was disagreement between the ultrasound and surgical reports, and additional fellowship-trained musculoskeletal radiologist with 15 years of musculoskeletal ultrasound experience was included for a consensus agreement. The diagnosis of tendinosis was made at ultrasound when a heterogeneous hypoechoic, ill-defined, thickened tendon was observed. Partial thickness tears were characterized by a focal hypoechoic or anechoic defect which extended to either bursal or articular/deep surface. Full-thickness tears were identified by the appearance of a tendon defect extending from articular to bursal surface. When there were no tendon fibers visualized at the lesser tuberosity insertion site in both long and short axis, diagnosis of a complete tear was made.

Sonographic examinations were performed using a 12-MHz compact linear array transducer (Model iU22, Philips Medical Imaging, Bothell, WA) by one of four diagnostic medical sonographers (2 to 10 years of experience of performing only musculoskeletal ultrasound examinations), supervised by one of 10 fellowship-trained musculoskeletal radiologists (range of experience from 2 – 11 years), as part of routine patient care. All patients presented with shoulder pain and were referred for sonographic evaluation of rotator cuff pathology. In all patients, ultrasound evaluation of subscapularis was started with patient's arm in neutral position, both short and long axis views of the tendon were then obtained by asking the patient to rotate the shoulder externally. It is important to move the transducer superiorly and inferiorly over the lesser tuberosity to ensure complete evaluation. Both static gray scale

images and cine clips were stored in the picture archive computer system.

3. RESULTS

The study group consisted of 19 patients (9 left and 10 right shoulders): 13 males and 6 females with a median age of 59 years (age range, 34-83 years). Ten patients underwent open surgical repairs and nine had arthroscopic repairs. The interval of time between the sonographic examination and the surgical repair ranged from 8 to 739 days (mean, 147 days).

Surgical results of the 19 patients showed tendinosis in 5% (1/19) (Fig. 1), partial thickness tear in 16% (3/19) (Fig. 2), full thickness tear in 42% (8/19) (Fig. 3), and complete subscapularis tear in 37% (7/19) (Fig. 4).

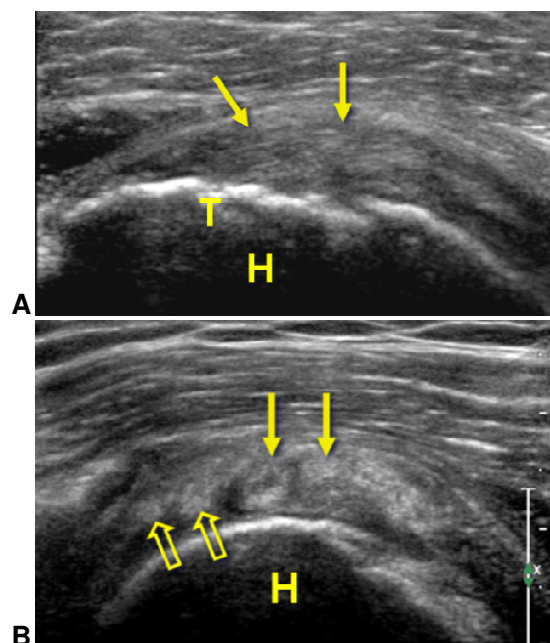


Fig. 1. 56-year-old male with diagnosis of subscapularis tendinosis

Ultrasound images long axis (A) and short axis (B) to the subscapularis tendon show heterogeneous hypoechoic, ill-defined, thickened tendon fibers (arrows). T = lesser tuberosity, H = humeral head. Note normal appearing inferior fibers (open arrows)

The correlation between sonographic and surgical findings is summarized in Table 1 and Fig. 5.

One hundred percent sonographic concordance was observed in tendinosis (n=1) and partial thickness tear (n=3). Of the 8 surgically proven full thickness tears, sonographic concordance

was 87.5%. In this group, 1 patient interpreted as complete tear by ultrasound was observed after surgery to have upper 2/3 of fibers torn, and there was 143 day time interval between ultrasound and repair. Of the 7 surgically proven complete tears, sonographic concordance was 57%, ultrasound underestimated 3 patients as partial thickness tear (n = 1) and full thickness tears (n = 2) with 240 days average time interval between ultrasound and surgical repair. Overall, there was 79% US concordance in diagnosing subscapularis tendon pathology when surgery is used as a gold standard.

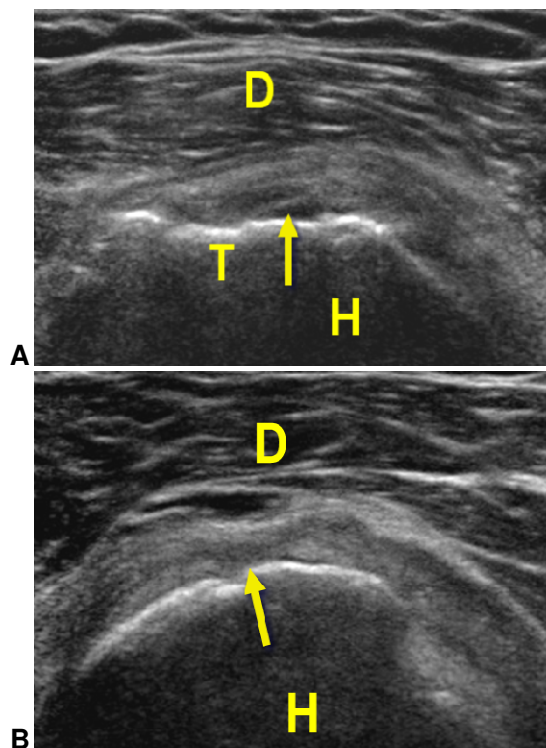


Fig. 2. 47-year-old male with diagnosis of a partial thickness tear of subscapularis tendon

Ultrasound images long axis (A) and short axis (B) to the subscapularis tendon show a focal hypoechoic/anechoic area that extends to the articular surface (arrow). D = deltoid muscle, T = lesser tuberosity, H = humeral head

4. DISCUSSION

As the largest and most powerful rotator cuff muscle, the subscapularis arises from the anterior scapula. Its upper two thirds inserts along with the capsule on the lesser tuberosity as four to six thick tendinous bands, while the inferior one third inserts on the humeral metaphysis as a muscular attachment [5,11,16-18] (Fig. 6).

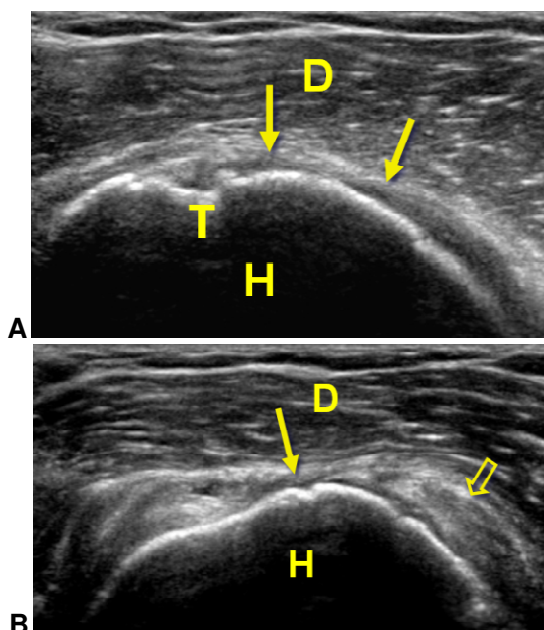


Fig. 3. 48-year-old female with diagnosis of focal full-thickness tear of superior fibers of the subscapularis tendon

Ultrasound images long axis (A) and short axis (B) to the subscapularis tendon demonstrates focal absence of superior aspect of subscapularis tendon (arrow). T = lesser tuberosity, D = deltoid muscle, H = humeral head. Note tendinosis (open arrow) of inferior fibers

Turkel et al. [2] described the role of the subscapularis in providing active internal rotation of the humerus and contributing to the dynamic anterior stability of the glenohumeral joint.

Compared with other rotator cuff tendons, a subscapularis tendon tear is infrequently identified as a major cause of shoulder pain and dysfunction. Previous reports have shown a relatively low incidence of the subscapularis tendon tear with a range of 2.1% to 10.5% [4,9,18,19]. Tearing of the subscapularis tendon associated with a supraspinatus tendon tear is considered more common and is predominantly the result of a degenerative process, while acute isolated subscapularis tearing occur rarely after traumatic injury in younger patients [5,11,18]. Two of 19 patients in our study suffered isolated subscapularis tears after acute injury.

Despite its infrequency, injury to the subscapularis tendon, particularly as a result of a complete tear, may lead to considerable changes to shoulder joint dynamics and stability. Correct diagnosis is therefore very important since early operative management can result in pain relief and restored shoulder function, particularly in

cases of acute full thickness and complete tear [9,17].

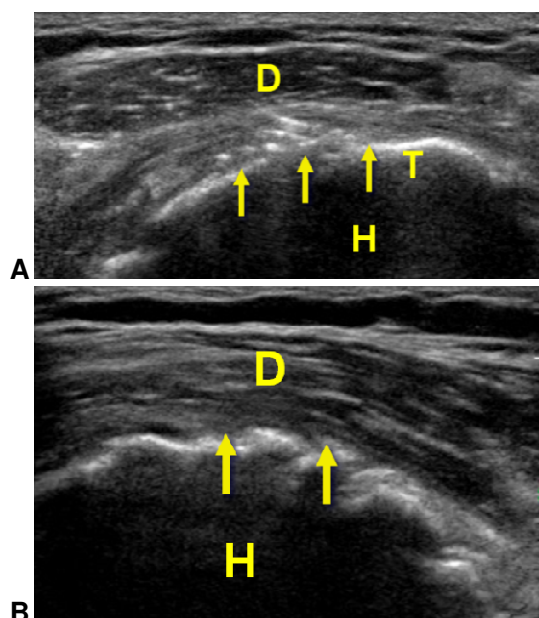


Fig. 4. 60-year-old man with diagnosis of complete tear of subscapularis tendon

Ultrasound images long axis (A) and short axis (B) to the subscapularis tendon shows absence of subscapularis tendon fibers (arrows). T = lesser tuberosity, D = deltoid muscle, H = humeral head

With advantages of high-resolution ultrasound allowing low-cost and convenient imaging, as well as ease of contralateral comparison and dynamic evaluation, previous studies have shown that US and MRI have comparable degrees of accuracy for diagnosing and measuring rotator cuff tears [12,13]. Our study showed best correlation of sonographic and surgical findings in cases of tendinosis and partial thickness tear with 100% concordance. In the group of 8 full thickness tears, optimal results reveal 87.5% sonographic concordance. One patient interpreted as a complete tear by US was found by open surgery to have the upper two-thirds fibers torn, with a time interval of 143 days between US and repair. Given this time interval, identifying the torn subscapularis tendon at open surgery may be challenging as a layer of scar tissue may form, and the tear could be missed [4,20,21]. In addition, previous reports in the literature have suggested that the evaluation of entire width and length of the subscapularis tendon maybe difficult during open procedures [22]. Although the prior literature describes

Table 1. US concordance Surgery

		Tendinosis	Partial	Full	Complete
Ultrasound	Tendinosis	1	0	0	0
	Partial	0	3	0	1
	Full	0	0	7	2
	Complete	0	0	1	4
	Total	1	3	8	7

Note: Highlighted numbers indicating surgical proven correct sonographic diagnoses

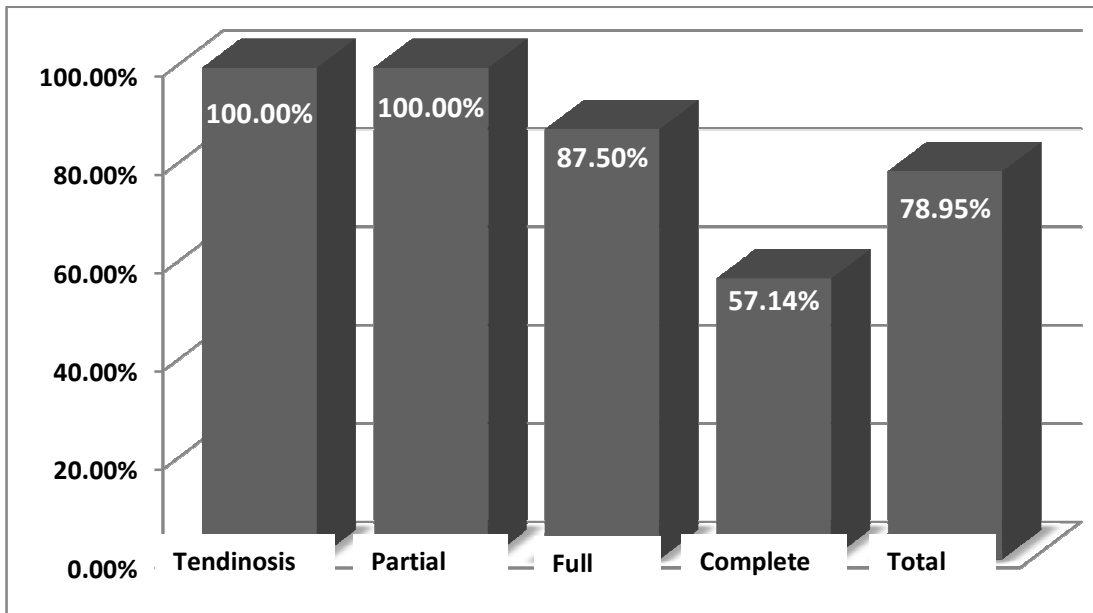


Fig. 5. Ultrasound diagnosis of tendinosis, partial thickness tear, full thickness tear, and complete tear with surgical correlation

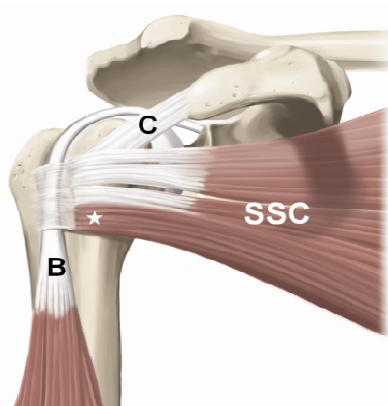


Fig. 6. Anatomy of the subscapularis tendon:
 Illustration of the anterior aspect of the shoulder shows the subscapularis (SSC) inserting on the lesser tuberosity with inferior muscular attachment (asterisk).
 B = long head biceps tendon, C = coracohumeral ligament

higher sensitivity of US in detecting larger rotator cuff tears [23], interestingly, a relatively low (57%) sonographic concordance was found in our seven complete tear group patients. All three of the complete tears at surgery that were underestimated as partial thickness or full thickness tears at ultrasound may be in part explained by the time interval between ultrasound and surgery in the complete tear group (240 days), as tears may have progressed between the ultrasound examination and surgery.

We acknowledge several limitations to our study. The retrospective nature of the study is one limitation as well as the small number of patients. Time interval (average 147 days) between US and surgery may affect our results of relative low sonographic concordance in group of larger tears. As a gold standard, subscapularis tendon tears may be difficult to visualize by arthroscopy

and at open surgery. Because our study group did not include surgically-proven normal subscapularis tendons, sensitivity, specificity, and accuracy of ultrasound in the diagnosis of subscapularis tears cannot be assessed. This will be a consideration with future studies.

5. CONCLUSION

In summary, US is useful in detection of subscapularis tendon pathology showing a 79% concordance rate. Sonographic findings of subscapularis tendinosis and partial thickness tears correlate best with surgery, while US may underestimate complete tears.

ETHICAL APPROVAL

Institutional review board approval was obtained before commencing this retrospective study with informed consent waived.

COMPETING INTERESTS

Authors have declared that no competing interests exist.

REFERENCES

1. Symeonides PP. The significance of the subscapularis muscle in the pathogenesis of recurrent anterior dislocation of the shoulder. *J Bone Joint Surg Br.* 1972;54(3):476-83.
2. Turkel SJ, et al. Stabilizing mechanisms preventing anterior dislocation of the glenohumeral joint. *J Bone Joint Surg Am.* 1981;63(8):1208-17.
3. Longo UG, et al. Subscapularis tears. *Med Sport Sci.* 2012;57:114-21.
4. Deutsch A, et al. Traumatic tears of the subscapularis tendon. Clinical diagnosis, magnetic resonance imaging findings, and operative treatment. *Am J Sports Med.* 1997;25(1):13-22.
5. Lyons RP, Green A. Subscapularis tendon tears. *J Am Acad Orthop Surg.* 2005;13(5):353-63.
6. Sakurai G, et al. Incomplete tears of the subscapularis tendon associated with tears of the supraspinatus tendon: cadaveric and clinical studies. *J Shoulder Elbow Surg.* 1998;7(5):510-5.
7. Gerber C, Hersche O, Farron A. Isolated rupture of the subscapularis tendon. *J Bone Joint Surg Am.* 1996;78(7):1015-23.
8. Kim TK, Rauh PB, McFarland EG. Partial tears of the subscapularis tendon found during arthroscopic procedures on the shoulder: a statistical analysis of sixty cases. *Am J Sports Med.* 2003;31(5):744-50.
9. Flury MP, et al. Rupture of the subscapularis tendon (isolated or in combination with supraspinatus tear): when is a repair indicated? *J Shoulder Elbow Surg.* 2006;15(6):659-64.
10. Mansat P, Frankle MA, Cofield RH. Tears in the subscapularis tendon: descriptive analysis and results of surgical repair. *Joint Bone Spine.* 2003;70(5):342-7.
11. Morag Y, et al. The subscapularis: anatomy, injury, and imaging. *Skeletal Radiol.* 2011;40(3):255-69.
12. De Jesus JO, et al. Accuracy of MRI, MR arthrography, and ultrasound in the diagnosis of rotator cuff tears: a meta-analysis. *AJR Am J Roentgenol.* 2009;192(6):1701-7.
13. Teefey SA, et al. Detection and quantification of rotator cuff tears. Comparison of ultrasonographic, magnetic resonance imaging, and arthroscopic findings in seventy-one consecutive cases. *J Bone Joint Surg Am.* 2004;86-A(4):708-16.
14. Ives EP, et al. Subscapularis tendon tears: a common sonographic finding in symptomatic postarthroplasty shoulders. *J Clin Ultrasound.* 2013;41(3):129-33.
15. Singiseti K, Hinsche A. Shoulder ultrasonography versus arthroscopy for the detection of rotator cuff tears: analysis of errors. *J Orthop Surg (Hong Kong).* 2011;19(1):76-9.
16. Arai R, et al. Subscapularis tendon tear: an anatomic and clinical investigation. *Arthroscopy.* 2008;24(9):997-1004.
17. Clark JM, Harryman DT. 2nd, Tendons, ligaments, and capsule of the rotator cuff. Gross and microscopic anatomy. *J Bone Joint Surg Am.* 1992;74(5):713-25.
18. Li XX, et al. MR evaluation of subscapularis tears. *J Comput Assist Tomogr.* 1999;23(5):713-7.
19. Kreuz PC, et al. Isolated and combined tears of the subscapularis tendon. *Am J Sports Med.* 2005;33(12):1831-7.
20. Gerber C, Krushell RJ. Isolated rupture of the tendon of the subscapularis muscle. Clinical features in 16 cases. *J Bone Joint Surg Br.* 1991;73(3):389-94.

21. Lee KW, et al. A comparison of conventional ultrasonography and arthrosonography in the assessment of cuff integrity after rotator cuff repair. Clin Orthop Surg. 2014;6(3):336-42.
22. Toussaint B, et al. New endoscopic classification for subscapularis lesions. Orthop Traumatol Surg Res. 2012;98(8):S186-92.
23. Farin PU, Jaroma H. Acute traumatic tears of the rotator cuff: value of sonography. Radiology. 1995;197(1):269-73.

© 2015 Dong et al.; This is an Open Access article distributed under the terms of the Creative Commons Attribution License (<http://creativecommons.org/licenses/by/4.0>), which permits unrestricted use, distribution, and reproduction in any medium, provided the original work is properly cited.

Peer-review history:

The peer review history for this paper can be accessed here:
<http://www.sciencedomain.org/review-history.php?iid=719&id=12&aid=6965>