

Corneal Cross Linking with Riboflavin for Progressive Keratoconus in Paediatric Eyes

Nishant Nawani*, Arun K. Jain, Chintan Singh

Department of Ophthalmology, Advanced Eye Centre, Post Graduate Institute of Medical Education and Research, Chandigarh, India

Email: [*nawani99@hotmail.com](mailto:nawani99@hotmail.com)

Received 25 June 2014; revised 26 July 2014; accepted 21 August 2014

Copyright © 2014 by authors and Scientific Research Publishing Inc.

This work is licensed under the Creative Commons Attribution International License (CC BY).

<http://creativecommons.org/licenses/by/4.0/>



Open Access

Abstract

Purpose: To report visual, refractive and topographic outcomes after corneal collagen crosslinking (CXL) for progressive keratoconus in paediatric eyes. **Methods:** In this prospective interventional study, twenty eyes of eighteen patients with progressive keratoconus were included. All eyes underwent CXL with riboflavin after documented progression of the disease. Informed, written consent was taken from the parents of the patients. The patients were followed up for 6 months. Complete ophthalmic examination and Scheimpflug imaging were performed at each visit. Reduction of the mean refractive cylinder, and corneal flattening were the main outcome measures. **Results:** The mean age of the patients was 13.55 years, (range: 9 - 16 yrs). The mean refractive cylinder reduced from a preoperative value of -5.26D to -4.66D ($p = 0.10$), -4.31D ($p = 0.009$), and, -4.10D ($p = 0.003$) at one, three and six months (postoperative) respectively. The mean average K value increased from 51.88D to 52.18D ($p = 0.64$) at one month postoperatively and reduced thereafter to 51.28D ($p = 0.32$) and 51.54D ($p = 0.02$) at three and six months respectively. Thinnest pachymetry reduced very significantly from a mean preoperative value of $459.15\ \mu\text{m}$ to $400.8\ \mu\text{m}$ ($p < 0.001$), $405.9\ \mu\text{m}$ ($p < 0.001$) and $413.6\ \mu\text{m}$ ($p < 0.001$) postoperatively at one, three and six months respectively. Best corrected visual acuity (decimal units) improved insignificantly from a preoperative value of 0.43 to 0.49 ($p = 0.42$) at six months postoperatively. **Conclusion:** Short term results of corneal collagen crosslinking with riboflavin for progressive keratoconus in children are promising in terms of reduction in the mean refractive cylinder and flattening of the cornea, and appears effective in halting the progression of the disease in the paediatric age group. Long term follow up is required to assess the lasting effect of CXL in this age group.

Keywords

Corneal Crosslinking, Progressive Keratoconus, Paediatric Eyes

*Corresponding author.

1. Introduction

Keratoconus is a slowly progressive, noninflammatory corneal degenerative disorder characterized by changes in corneal collagen structure and organization [1]-[3]. Decreased mechanical corneal stability plays an important role in the progressive protrusion of the keratoconic cornea, resulting in mild to marked impairment of visual acuity owing to irregular astigmatism, progressive myopia, corneal thinning, and central corneal scarring [4]. The 3-dimensional configuration of the collagen lamella fundamentally codetermines the cornea's resistance. Biochemical and immunohistochemical studies of the matrix's proteoglycans show differences between normal and keratoconic corneas [5]-[8]. Enzymatic alterations with an increased expression proteolytic enzymes, [6] [9]-[11] decreased concentration of protease inhibitors [9] [12] and modified configuration of the stromal collagen lamella [13] have been observed.

Diagnosis of keratoconus in childhood is a negative prognostic factor for progression, increasing the probability of the need for corneal transplantation [14]. Younger patients are particularly at risk for faster progression of the disease [14] [15]. Corneal collagen cross-linking (CXL), stabilizes progressive keratoconus, prevents some of the underlying pathophysiologic mechanisms of the disease, and avoids the need for penetrating keratoplasty [15]. CXL increases the biomechanical strength of the human cornea by about 300% by the combined action of a photosensitizing substance (riboflavin) and ultraviolet (UV) light from a solid-state UVA source [16]. The treatment creates additional chemical bonds inside the anterior 200 - 300 microns of the corneal stroma by means of photopolymerization. In this study we examined the refractive and tomographic outcomes of CXL in paediatric patients with progressive keratoconus.

2. Materials and Methods

Forty one eyes of 34 consecutive patients were included in this prospective, non-randomized comparative study. Diagnosis of keratoconus was based on slit lamp findings and/or corneal images generated by Pentacam rotating Scheimpflug imaging system (Oculus Optikgerate GmbH, Wetzlar, Germany). Patients who had documented progression of keratoconus in the last six months *i.e.*, change in refraction (>1D cylinder, 0.5D spherical), increase in steep keratometry value > 1D, progressive corneal thinning (>5% decrease) and corneal thickness > 400 μm at the thinnest point were included in the study. Exclusion criteria included any patient with history of ophthalmic surgery, corneal scarring or any significant ophthalmic disease other than keratoconus. Patients were divided into two groups; Group 1 included keratoconus patients in paediatric age group *i.e.* age \leq 16 yrs (n = 20), whereas Group 2 included keratoconus patients >16 yrs (n = 21). All eyes underwent an extensive ophthalmologic examination that included visual acuity measurements, manifest refraction, slit lamp biomicroscopy, Goldmann tonometry, and fundus examination. The study followed the tenets of the Declaration of Helsinki and was approved by the Institutional review board. Informed consent was obtained from parents of each subject (<18 years of age) or from the patient itself after explanation of the nature of the study.

2.1. Surgical Technique

The surgical procedure of corneal cross-linking induced by riboflavin and UVA was performed in all patients according to a modification of the Siena protocol [17].

The procedure was performed on a day care basis. Pre-operative antibiotic drop (moxifloxacin 0.5%) was instilled 2 hourly one day prior to surgery whereas 2% pilocarpine drops three times 1 hr prior to procedure. Under topical anaesthesia with 0.5% proparacaine and after applying a lid speculum, the cornea was de-epithelised over 8 mm diameter with a blunt spatula. Photosensitizing riboflavin 0.1% + 20% dextran (Ricrolin; Sooft, Montegiorgio, Italy), was applied every 5 minutes for 30 minutes to achieve adequate penetration of the solution. The eye was then irradiated for 30 minutes with UVA of 370 nm wavelength at a working distance of 54 mm with an irradiance of 3 mW/cm² using a VEGA X-linker (Costruzione Strumenti Oftalmici, Florence, Italy). Riboflavin solution was applied once every 5 minutes during irradiation. At the end of the procedure, saline wash given to cornea and conjunctiva to remove excess riboflavin and antibiotics drops instilled. A soft bandage contact lens was applied.

2.2. Follow up

Patients were seen at the clinic daily until re-epithelization was complete. Postoperatively, topical moxifloxacin

0.5% was prescribed tid for 2 weeks along with a combination of topical tobramycin 0.3% + flurometholone 0.1% tid for 4 weeks. Topical carboxymethylcellulose 0.5% was prescribed qid for 2 - 3 months. The therapeutic contact lens was removed on the 4th postoperative day in most cases. Subsequent examinations were at 1, 3, and 6 months. At each examination, refraction, best corrected visual acuity (BCVA) with glasses, Pentacam Scheimpflug imaging (Oculus Optikgerate GmbH, Wetzlar, Germany), central corneal thickness (CCT), and intraocular pressure (IOP) were recorded.

2.3. Statistical Analysis

Statistical analysis was performed with SPSS software version 17. Paired T-test was applied to compare the means within each group. Independent T-test was applied to compare the significant difference between the means of both groups. $p \leq 0.05$ was considered significant.

3. Results

Baseline characteristics of both groups are shown in **Table 1**. The mean preoperative cylindrical refractive error and average K values were significantly higher in the younger age group. The M:F ratio was higher in the younger age group.

In both groups the mean decimal BCVA reduced insignificantly (**Figure 1**) at 1 month follow up and improved thereafter at 3 and 6 months postoperatively. In Group 2 there was a statistically significant improvement in BCVA between 1 month and three months (mean change +0.08; $p = 0.008$) and between one and 6 months postoperatively (mean change +0.09; $p = 0.004$). When both groups were compared, the BCVA was significantly better in the Group 2 only at the 3 month follow up ($p = 0.042$), the difference in BCVA being insignificant at 6 months.

In Group 1, the mean spherical refractive error increased insignificantly from a mean preoperative value of $-2.5D$ to $-3.2D$ at 3 months and $-4.4D$ at 6 months postoperatively. Whereas in Group 2 the mean spherical refractive error reduced insignificantly from $-3.4D$ preoperatively to $-3.2D$ and $-2.6D$ at the 3 & 6 month follow up respectively (**Figure 2**).

The mean preoperative refractive cylinder error in Group 1 (**Figure 3**), reduced significantly from a preoperative value of $-5.3D$ to $-4.3D$ ($p = 0.009$) and $-4.1D$ ($p = 0.003$) at 3 & 6 months respectively. In Group 2, the mean preoperative cylinder was $-2.5D$, which increased to $-3.2D$ at the 1st month ($p = 0.159$) and reduced thereafter to $-2.7D$ ($p = 0.728$) and $-2.3D$ ($p = 0.923$) at 3 & 6 months respectively. There was a statistically significant decrease between the mean cylinder at 1 month and 6 months postoperatively (mean change $-0.9D$; $p = 0.018$).

The spherical equivalent of refraction (**Figure 4**) increased in Group 1 from a preoperative value of $-5.1D$ to $-5.4D$ ($p = 0.53$) and $-6.4D$ ($p = 0.58$) at 3 & 6 months respectively, whereas it decreased in Group 2 from a preoperative value of $-4.6D$ to $-4.5D$ ($p = 0.85$) and $-3.8D$ ($p = 0.5$) at 3 & 6 months postoperatively.

In Group 1 the mean average K (**Figure 5**) increased from a preoperative value of $51.9D$ to $52.2D$ ($p = 0.636$) at the 1st month follow up. Thereafter it reduced to $51.3D$ ($p = 0.327$) and $51.5D$ ($p = 0.015$) at 3 & 6 months postoperatively. The difference between the mean average K value at one and three months (mean change $-0.9D$;

Table 1. Group demographics (baseline).

Characteristic	Group 1 (n = 20)	Group 2 (n = 21)	p value
Age (yrs)	13.55 ± 2.781 Range: 9 - 16	23.95 ± 5.123 Range: 18 - 41	$p < 0.0001$
Gender (M:F)	17:3	8:13	
BCVA (decimal)	0.43 ± 0.18	0.54 ± 0.20	$p = 0.082$
Mean Sphere (D)	-2.51 ± 3.47	-3.37 ± 3.69	$p = 0.449$
Mean Cylinder (D)	-5.26 ± 1.67	-2.50 ± 2.70	$p < 0.0001$
Sphere Eq. (D)	-5.14 ± 3.22	-4.62 ± 2.69	$p = 0.0628$
Avge K (D)	51.89 ± 5.53	48.91 ± 2.83	$p = 0.035$
CCT (µm)	459.75 ± 36.21	477.38 ± 40.66	$p = 0.151$

$p = 0.025$) and one and six months follow up (mean change $-0.6D$; $p = 0.012$) was statistically significant. In Group 2 the mean average K increased significantly from a preoperative value of $48.9D$ to $49.7D$ at the first month ($p = 0.026$) and then showed improvement to $48.9D$ at three months ($p = 0.905$) and $47.8D$ at six months respectively ($p = 0.172$). There was a statistically significant decrease in average K from 1 month to 3 months

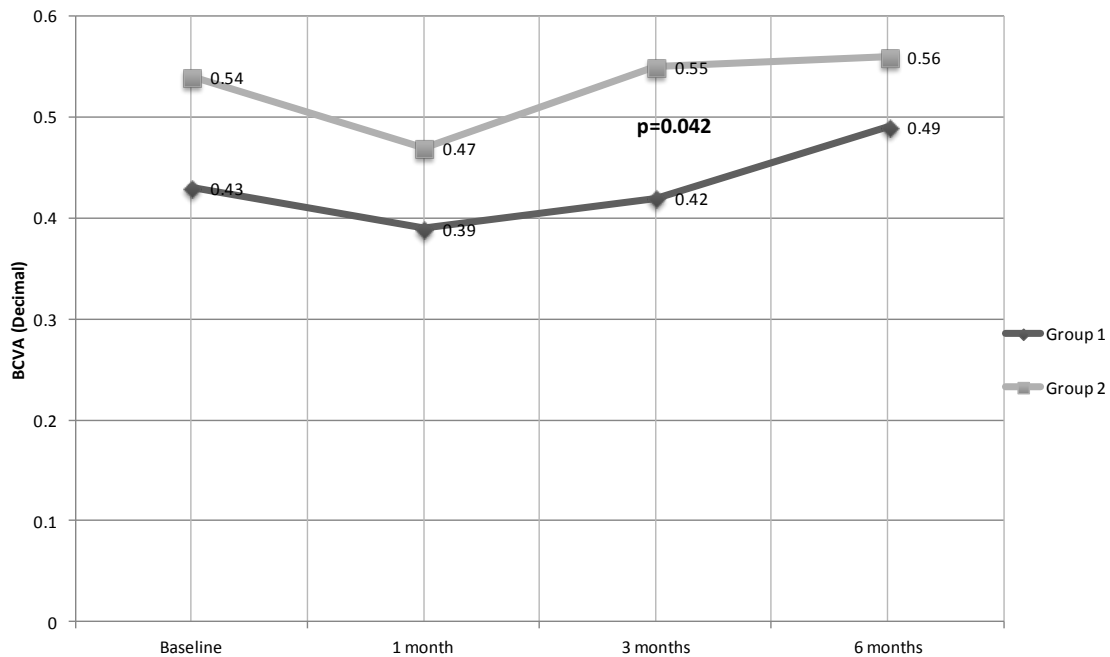


Figure 1. Comparison of change in mean decimal BCVA. Both groups had reduced BCVA at the first month follow up after which BCVA improved. Both Groups 1 & 2 had significant improvement in BCVA between the 1 month follow and the 6 month follow up ($p = 0.017$ and $p = 0.004$) respectively. Mean decimal BCVA was significantly better in Group 2 only at the 3 month follow up ($p = 0.042$).

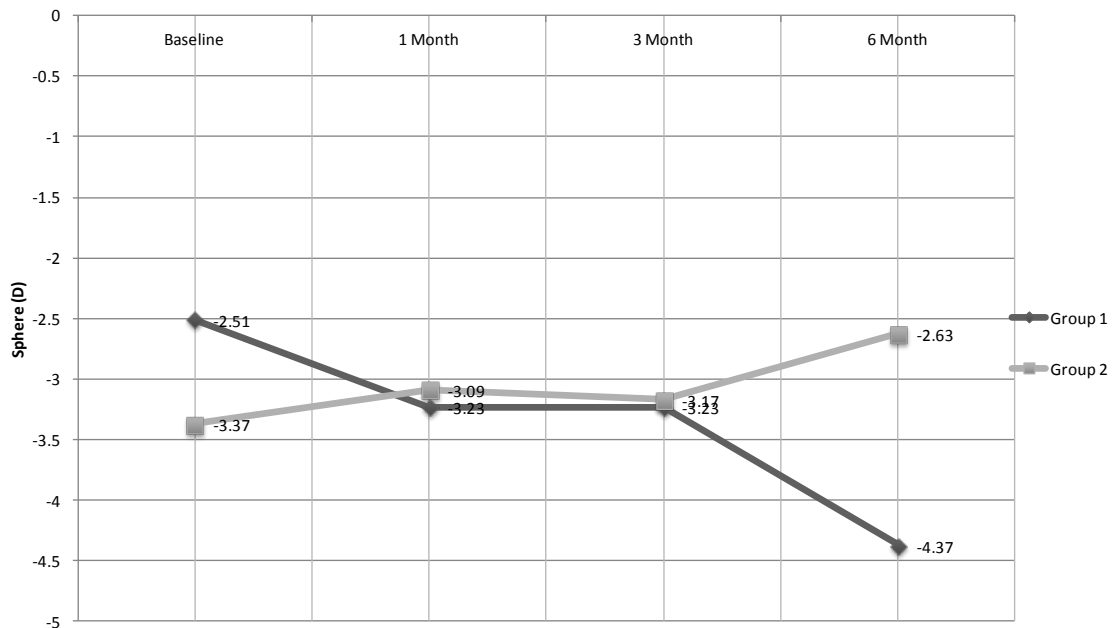


Figure 2. Comparison of change in mean spherical error of refraction (D). Mean spherical error of refraction increased insignificantly in Group 1 whereas it decreased insignificantly in Group 2. There was no significant difference between the postoperative observations.

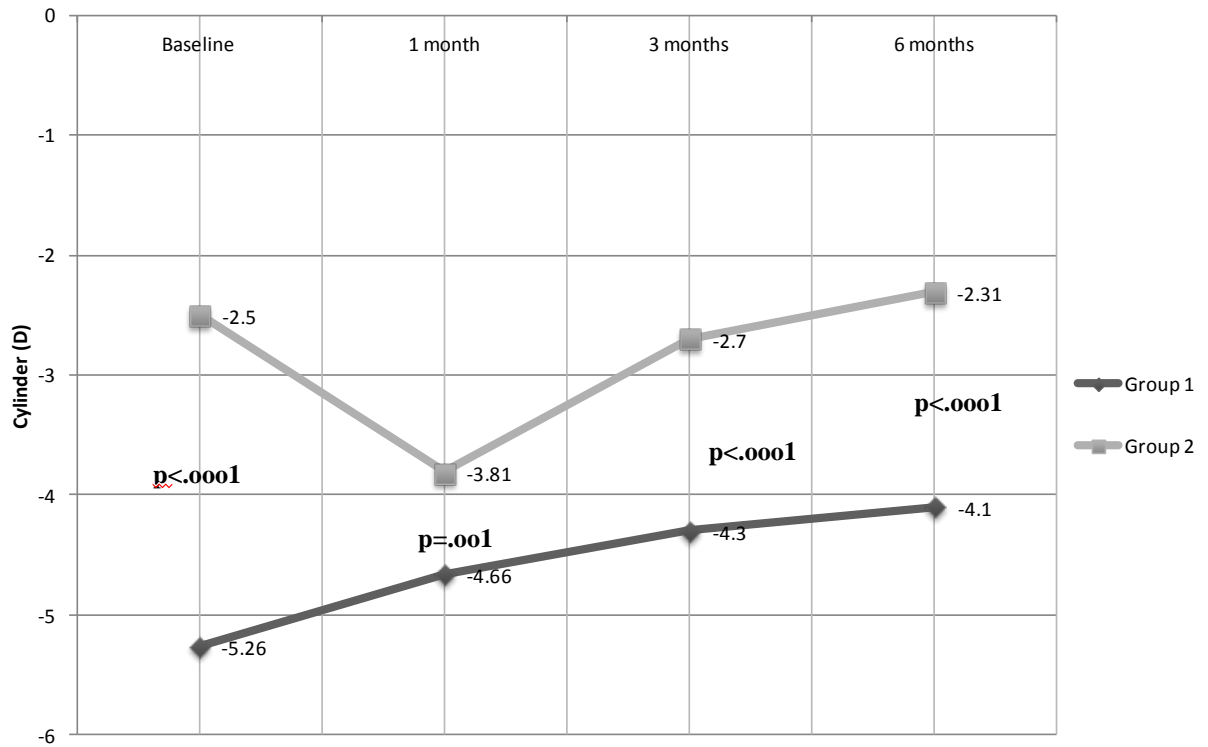


Figure 3. Comparison of change in refractive cylinder (D). Mean refractive cylinder reduced in both groups at the 6 months postop. The change however was significant in Group 1. After adjusting for the significant difference between preoperative means between both groups, there was a statistically significant lower mean cylinder in Group 2 at all follow up observations.

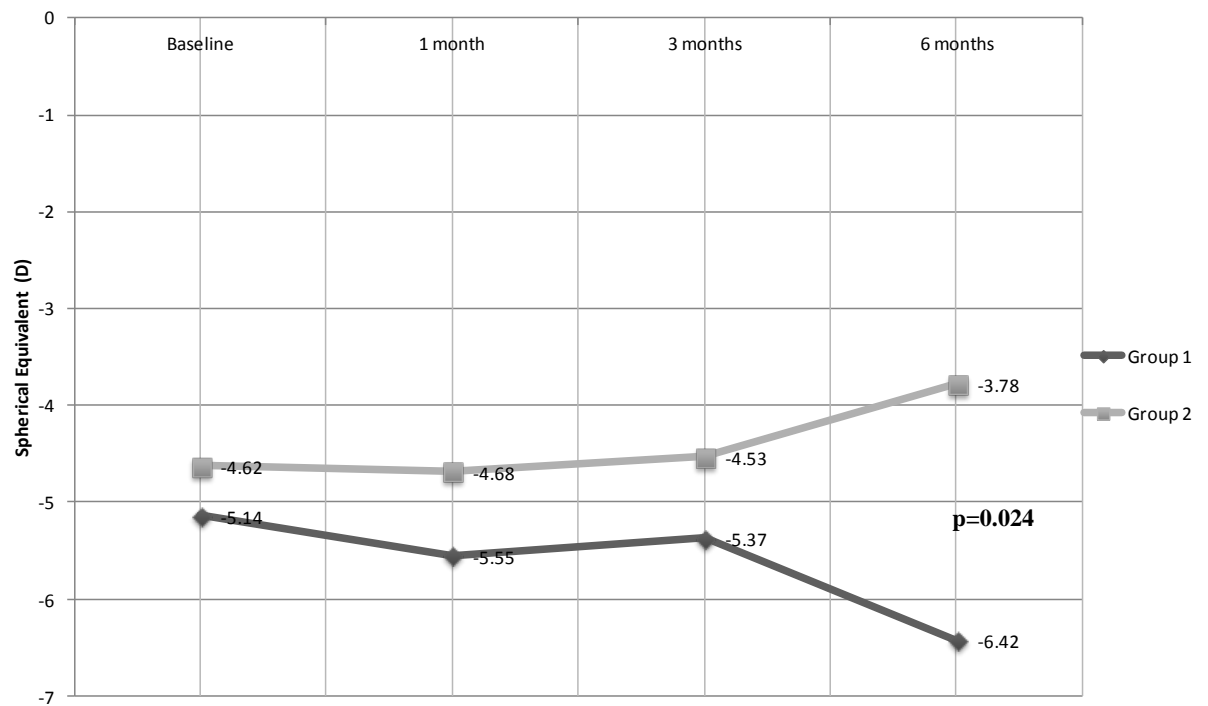


Figure 4. Comparison of change in spherical equivalent of refraction (D). The Mean Spherical Equivalent of Refraction worsened in Group 1 whereas it improved in Group 2. The difference between both groups was statistically significant at 6 months follow up ($p = 0.024$).

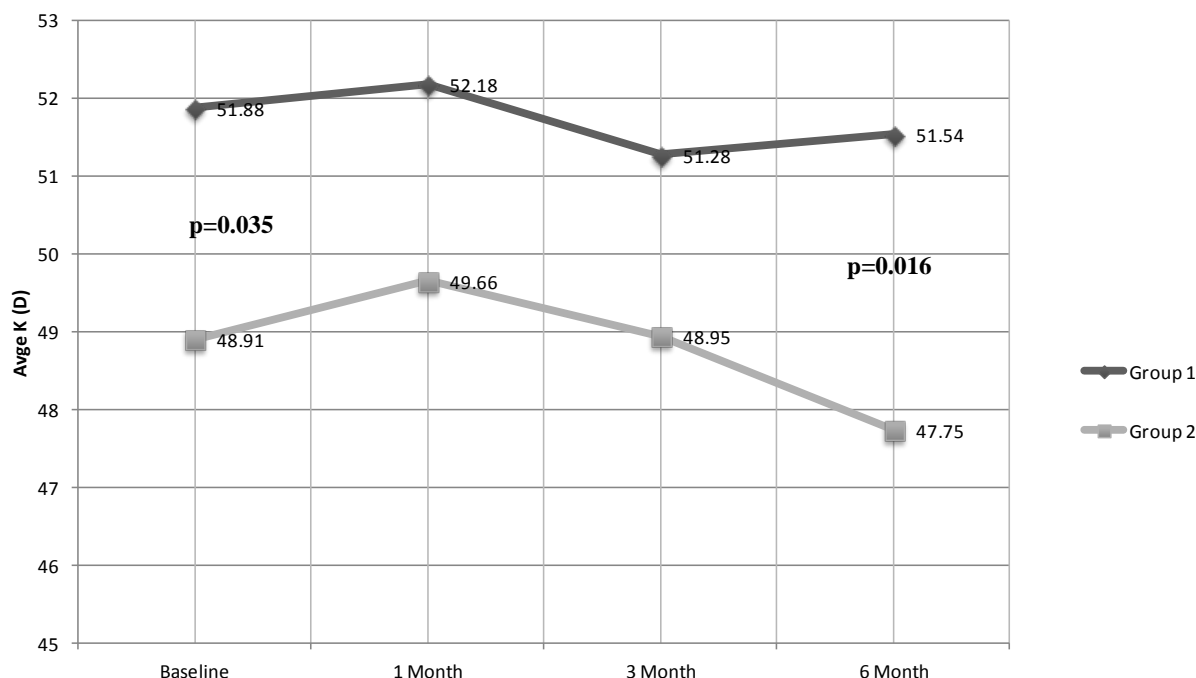


Figure 5. Comparison of change in Mean Average K (D). Both Groups showed worsening of K value at 1 month, which showed improvement at three and six months follow up. During follow up this difference between both groups was significant at 6 months only ($p = 0.016$).

postoperatively (mean change $-0.7D$, $p = 0.002$) and between 1 month and 6 months postoperatively (mean change $-1.91D$, $p < 0.001$).

The thinnest pachymetry (**Figure 6**) reduced significantly in Group 1 from $459.1 \mu\text{m}$ at baseline to $400.8 \mu\text{m}$ ($p < 0.001$), $405.9 \mu\text{m}$ ($p < 0.001$) and $413.6 \mu\text{m}$ ($p < 0.001$) at one, three and six months respectively. In Group 2 as well the thinnest pachymetry reduced significantly from $477.3 \mu\text{m}$ at baseline to $429.8 \mu\text{m}$ ($p < 0.0001$), $438.6 \mu\text{m}$ ($p < 0.0001$), $446.3 \mu\text{m}$ ($p < 0.0001$) at one, three and six months respectively.

4. Discussion

This study compares the short term results of corneal collagen crosslinking with riboflavin for progressive keratoconus between adult and paediatric corneas. In this non-randomized study we analyzed and compared visual acuity, refractive, topographic and pachymetric outcomes in both groups with no procedure related complications.

Both groups showed marginal (insignificant) improvement in BCVA (**Figure 1**) at six months when compared to baseline. BCVA dropped at the 1 month follow up in both groups which was due to postoperative stromal haze and corneal edema which has been shown to be detectable clinically at one month postoperatively in 70% of patients post crosslinking [17]. In a large longitudinal study by Raiskup-Wolf *et al.* [18] 53% of 142 eyes showed significant improvement in BCVA in the first year. More recently the ‘‘Siena CXL Pediatrics’’ trial involving 152 patients aged 18 years or younger showed significant improvement in BCVA of $+0.15 - +0.16$ Snellen lines at 36 months [19]. In their study, they found that final BCVA was better in the Group which had a corneal thickness $> 450 \mu\text{m}$ at the time of enrollment because of an earlier stage of keratoconus at the time. Our patients had a follow up of 6 months. Perhaps a longer follow up would be needed to show a significant improvement in BCVA.

The mean spherical refractive error (**Figure 2**) and the spherical equivalent (S Eq.) of refraction (**Figure 4**) increased in the younger age group whereas it improved in the older group. The difference in the S Eq. between both groups was significant at 6 months ($p = 0.024$) postoperatively. We did not measure axial lengths in our patients at any point in the study. Either progression of keratoconus or increasing axial length would explain this myopic shift in the younger age group. The improvement of S Eq. in the older group was $0.9D$ which is compa-

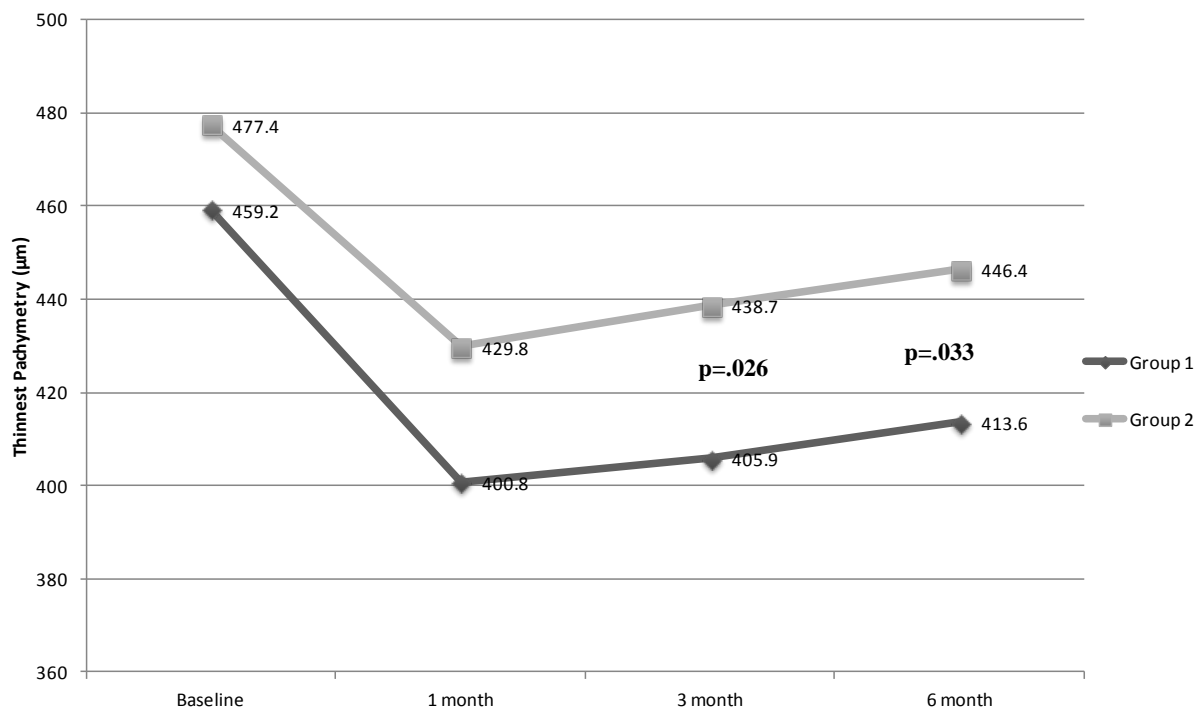


Figure 6. Comparison of change in thinnest pachymetry (µm). Thinnest pachymetry reduced significantly at all follow ups in both groups from baseline. The difference between both groups was significant at the third (p = 0.026) and six month (p = 0.033) follow up.

able to previous studies (Table 2). In Group 1 the mean refractive cylinder reduced significantly at 6 months by 1.16D (p = 0.003). In the older group (Figure 3) the mean refractive cylinder worsened in the initial two follow ups and then reduced insignificantly by 0.19D at the 6 month follow up. Caporossi *et al.* [17], in their series of 44 patients (age range 10 - 40 years) reported initial worsening of mean refractive cylinder in the first three months following crosslinking followed by an insignificant mean reduction by -0.52D at one year.

The average K value reduced significantly by 0.34D in Group 1 at 6 months. This decrease, though of a larger magnitude in Group 2 (-1.16D), did not approach statistical significance. The difference between both groups was significant at 6months. It remains unclear why the magnitude of reduction in the younger age group was less as compared to the older group and previous reports (Table 2). In the Siena CXL Pediatrics trial [19], the average K reduction in the thicker group (patients aged 18 years or younger with preoperative corneal thickness > 450 µm) was statistically significant at 12 months (mean change -0.46D; p = 0.0051). In the same study, the average K reduction in the thinner group (patients with preoperative corneal thickness < 450 µm) was statistically significant at 12 months (mean change -0.45D, p = 0.0048). The pediatric group, in our study showed statistically significant mean change of -0.34D at 6 months (p = 0.015). In both groups there was increase in average K at one month followed by a decrease at 3 and 6 months. This was similar to the trend reported by Vinciguerra *et al.* [21] and Hersh *et al.* [22] (Figure 7) but in contrast to continued decrease in average K postoperatively as reported by Caporossi *et al.* [17] and Raiskup-Wolf *et al.* [18] Confocal microscopy post crosslinking shows a time dependent stratification of the corneal epithelium after three months of the procedure [23]. This corresponds to a smoothing of the surface irregularities as the epithelium remodels/heals. This could explain the worsening of average K values in the initial follow up followed by improvement at the 3 month follow up as shown by our study.

Pachymetry measurements in our study were taken by means Pentacam optical pachymetry. In Group 1 the thinnest pachymetry reduced significantly at 3 months (mean change -53.25 µm, p < 0.001) and 6 months (mean change -45.53 µm, p < 0.001) when compared to baseline. In the older Group, reduction in thinnest pachymetry was lesser in magnitude (mean change -38.72 µm, p < 0.0001; and -31.0 µm, p < 0.0001 at three and six months respectively) but statistically significant. This reduction in thinnest pachymetry can be attributed to measurement artifact as it has been shown that optical pachymetry is affected negatively by the non-homogen-

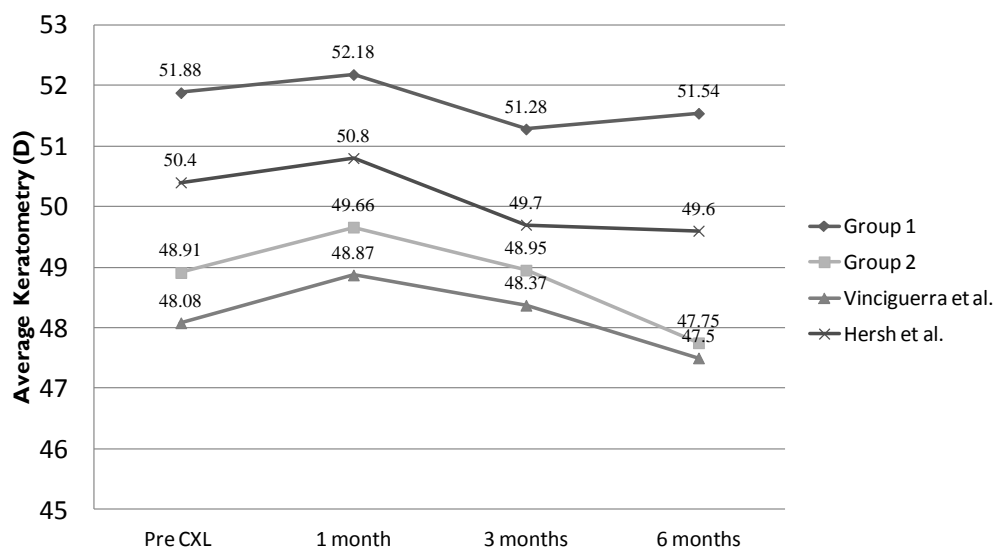


Figure 7. Comparison of progression of average keratometry (D). Initial worsening of K values at the 1 month follow up, followed by recovery at around 3 months post crosslinking.

Table 2. Comparison of results with previous studies.

Study/Year	Mean Age (years)	No. of Eyes	Follow up	Reduction in Mean Sphere	Reduction in Mean Cylinder	Improvement in S Eq.	Reduction in Average K value
Current Study/2011							
Group 1	13.55	20	6 months	(worse 1.86D)	1.16D	(Worse 1.28D)	0.34D
Group 2	23.95	21	6 months	0.74D	0.19D	0.9D	1.16D
Wollensak <i>et al.</i> [20]/2003	32.13	23	23.2 months	NA	NA	1.14D	2.01D in 70% eyes
Raiskup-Wolf <i>et al.</i> [18]/2008*	>18	241	12 months	NA	0.93D (in 50% eyes) Stable <i>i.e.</i> within \pm 0.50D in 36%	NA	1.46D in 56% eyes. Stable <i>i.e.</i> within \pm 0.50D in 30%
Vinciguerra <i>et al.</i> [21]/2009	24 - 52 (Range)	28	12 months	0.28D	0.26D	0.41D	0.58D at 6 months 6.07D at 1 year
Caporossi <i>et al.</i> [17]/2010 (The Siena Eye Cross Study)	10 - 40 (Range)	44	52.4 months	1.62D at 1 year	0.52D at 1 year	1.87 D at 1 year	1.96D at 1 year
Hersh <i>et al.</i> [22]/2011	\geq 14 yrs	49	12 months	NA	0.08D	0.85D	1.5D

*Shown in this table is the data for 142 eyes that completed follow up of one year.

ous optical changes seen in crosslinked corneas (due to corneal haze/demarcation line/stromal edema) [23] [24]. The Siena Study group [17] compared pachymetric results of the optical Orbscan IIz with ultrasound pachymetry and confocal pachymetric examinations and found a significant underestimation ($-120 \mu\text{m}$ in the first six months) of corneal thickness with the Orbscan IIz. Ultrasound and confocal postoperative pachymetric data did not show significant differences with respect to preoperative values. They concluded that confocal data and ultrasound pachymetry seemed to be less influenced by corneal collagen crosslinking induced stromal microstructural changes, providing more reliable postoperative pachymetric measurements. Some of the thinning observed postoperatively may be attributed to stromal “compression/compaction” as a result of increased number of crosslinks between adjacent collagen lamellae in the stroma.

In summary, post crosslinking, visual acuity and corneal steepness worsen at the 1 month time point. Resolution to baseline occurs approximately at the 3 month interval, with improvement thereafter. The older group appeared to have benefitted from the procedure, in terms of halt of progression of keratoconus. The mean spherical equivalent of refraction in the younger age group showed a continuous worsening up to the 6 month time point, despite improvement in mean cylindrical error and topography. The question remains that was this increasing

myopia or keratoconus progression. Perhaps following up younger patient with serial axial length measurements in future studies would address this issue.

Conflict of Interests

The authors have no financial or proprietary interest in the subject matter of this paper.

References

- [1] Tuori, A.J., Virtanen, I., Aine, E., *et al.* (1997) The Immunohistochemical Composition of Corneal Basement Membrane in Keratoconus. *Current Eye Research*, **16**, 792-801. <http://dx.doi.org/10.1076/ceyr.16.8.792.8989>
- [2] Cheng, E.L., Maruyama, I., SundarRaj, N., *et al.* (2001) Expression of Type XII Collagen and Hemidesmosome-Associated Proteins in Keratoconus Corneas. *Current Eye Research*, **22**, 333-340. <http://dx.doi.org/10.1076/ceyr.22.5.333.5491>
- [3] Radner, W., Zehetmayer, M., Skorpik, Ch. and Mallinger, R. (1998) Altered Organization of Collagen in Apex of Keratoconus Corneas. *Ophthalmic Research*, **30**, 327-332. <http://dx.doi.org/10.1159/000055492>
- [4] Rabinowitz, Y.S. (1998) Keratoconus. *Survey of Ophthalmology*, **42**, 297-319. [http://dx.doi.org/10.1016/S0039-6257\(97\)00119-7](http://dx.doi.org/10.1016/S0039-6257(97)00119-7)
- [5] Funderburgh, J.L., Panjwani, N., Conrad, G.W. and Baum, J. (1989) Altered Keratan Sulfate Epitopes in Keratoconus. *Investigative Ophthalmology Visual Science*, **30**, 2278-2281.
- [6] Rehany, U., Lahav, M. and Shoshan, S. (1982) Collagenolytic Activity in Keratoconus. *Annals of Ophthalmology*, **14**, 751-754.
- [7] Sawaguchi, S., Yue, B.Y.J.T., Chang, I., *et al.* (1991) Proteoglycan Molecules in Keratoconus Corneas. *Investigative Ophthalmology Visual Science*, **32**, 1846-1853.
- [8] Wollensak, J. and Buddecke, E. (1990) Biochemical Studies on Human Corneal Proteoglycans—A Comparison of Normal and Keratoconic Eyes. *Graefe's Archive for Clinical and Experimental Ophthalmology*, **228**, 517-523. <http://dx.doi.org/10.1007/BF00918483>
- [9] Kao, W.W.-Y., Vergnes, J.-P., Ebert, J., *et al.* (1982) Increased Collagenase and Gelatinase Activities in Keratoconus. *Biochemical and Biophysical Research Communications*, **107**, 929-936. [http://dx.doi.org/10.1016/0006-291X\(82\)90612-X](http://dx.doi.org/10.1016/0006-291X(82)90612-X)
- [10] Sawaguchi, S., Yue, B.Y.J.T., Sugar, J. and Gilboy, J. (1989) Lysosomal Enzyme Abnormalities in Keratoconus. *Archives of Ophthalmology*, **107**, 1507-1510.
- [11] Zhou, L., Sawaguchi, S., Twining, S.S., Sugar, J., Feder, R.S. and Yue, B.Y. (1998) Expression of Degradative Enzymes and Protease Inhibitors in Corneas with Keratoconus. *Investigative Ophthalmology & Visual Science*, **39**, 1117-1124.
- [12] Kenney, M.C., Nesburn, A.B., Burgeson, R.E., Butkowski, R.J. and Ljubimov, A.V. (1997) Abnormalities of the Extracellular Matrix in Keratoconus Corneas. *Cornea*, **16**, 345-351. <http://dx.doi.org/10.1097/00003226-199705000-00016>
- [13] Daxer, A. and Fratzl, P. (1997) Collagen Fibril Orientation in the Human Corneal Stroma and Its Implication in Keratoconus. *Investigative Ophthalmology & Visual Science*, **38**, 121-129.
- [14] Reeves, S.W., Stinnett, S., Adelman, R.A. and Afshari, N.A. (2005) Risk Factors for Progression to Penetrating Keratoplasty in Patients with Keratoconus. *American Journal of Ophthalmology*, **140**, 607.e1-607.e6. <http://dx.doi.org/10.1016/j.ajo.2005.05.029>
- [15] Wollensak, G. (2006) Crosslinking Treatment of Progressive Keratoconus: New Hope. *Current Opinion in Ophthalmology*, **17**, 356-360. <http://dx.doi.org/10.1097/01.icu.0000233954.86723.25>
- [16] Wollensak, G., Spoerl, E. and Seiler, T. (2003) Stress-Strain Measurements of Human and Porcine Corneas after Riboflavin-Ultraviolet-A-Induced Cross-Linking. *Journal of Cataract & Refractive Surgery*, **29**, 1780-1785. [http://dx.doi.org/10.1016/S0886-3350\(03\)00407-3](http://dx.doi.org/10.1016/S0886-3350(03)00407-3)
- [17] Caporossi, A., Mazzotta, C., Baiocchi, S. and Caporossi, T. (2010) Long-Term Results of Riboflavin Ultraviolet A Corneal Collagen Cross-Linking for Keratoconus in Italy: The Siena Eye Cross Study. *American Journal of Ophthalmology*, **149**, 585-593. <http://dx.doi.org/10.1016/j.ajo.2009.10.021>
- [18] Raiskup-Wolf, F., Hoyer, A., Spoerl, E. and Pillunat, L.E. (2008) Collagen Crosslinking with Riboflavin and Ultraviolet-A in Keratoconus: Long-Term Results. *Journal of Cataract & Refractive Surgery*, **34**, 796-801. <http://dx.doi.org/10.1016/j.jcrs.2007.12.039>
- [19] Caporossi, A., Mazzotta, C., Baiocchi, S., Caporossi, T., Denaro, R. and Balestrazzi, A. (2012) Riboflavin-UVA-In-

- duced Corneal Collagen Cross-Linking in Pediatric Patients. *Cornea*, **31**, 227-231. <http://dx.doi.org/10.1097/ICO.0b013e31822159f6>
- [20] Wollensak, G., Spoerl, E. and Seiler, T. (2003) Riboflavin/Ultraviolet-A-Induced Collagen Crosslinking for Treatment of Keratoconus. *American Journal of Ophthalmology*, **135**, 620-627. [http://dx.doi.org/10.1016/S0002-9394\(02\)02220-1](http://dx.doi.org/10.1016/S0002-9394(02)02220-1)
- [21] Vinciguerra, P., Albe, E., Trazza, S., Rosetta, P., Vinciguerra, R., Seiler, T. and Epstein, D. (2009) Refractive, Topographic, Tomographic, and Aberrometric Analysis of Keratoconic Eyes Undergoing Corneal Cross-Linking. *Ophthalmology*, **116**, 369-378. <http://dx.doi.org/10.1016/j.ophtha.2008.09.048>
- [22] Hersh, P.S., Greenstein, S.A. and Fry, K.L. (2011) Corneal Collagen Crosslinking for Keratoconus and Corneal Ectasia: One-Year Results. *Journal of Cataract & Refractive Surgery*, **37**, 149-160. <http://dx.doi.org/10.1016/j.jcrs.2010.07.030>
- [23] Mazzotta, C., Traversi, C., Baiocchi, S., Caporossi, O., Bovone, C., Sparano, M.C., Balestrazzi, A. and Caporossi, A. (2008) Corneal Healing after Riboflavin Ultraviolet-A Collagen Cross-Linking Determined by Confocal Laser Scanning Microscopy *in Vivo*: Early and Late Modifications. *American Journal of Ophthalmology*, **146**, 527-533. <http://dx.doi.org/10.1016/j.ajo.2008.05.042>
- [24] Mazzotta, C., Balestrazzi, A., Traversi, C., Baiocchi, S., Caporossi, T., Tommasi, C. and Caporossi, A. (2007) Treatment of Progressive Keratoconus by Riboflavin-UVA-Induced Cross-Linking of Corneal Collagen: Ultrastructural Analysis by Heidelberg Retinal Tomograph II *in Vivo* Confocal Microscopy in Humans. *Cornea*, **26**, 390-397. <http://dx.doi.org/10.1097/ICO.0b013e318030df5a>

Scientific Research Publishing (SCIRP) is one of the largest Open Access journal publishers. It is currently publishing more than 200 open access, online, peer-reviewed journals covering a wide range of academic disciplines. SCIRP serves the worldwide academic communities and contributes to the progress and application of science with its publication.

Other selected journals from SCIRP are listed as below. Submit your manuscript to us via either submit@scirp.org or [Online Submission Portal](#).

