



Short term Video EEG is a useful Diagnostic Procedure in Sub Acute Sclerosing Panencephalitis (SSPE)

Sajeesh Parameswaran^{1*}, T. V. Anil Kumar¹, M. Ajith¹, B. K. Athira¹, Archana Krishnan¹, Nandana Murali¹ and A. Marthanda Pillai¹

¹*Department of Neuroscience, Ananthapuri Hospitals and Research Institute, Trivandrum, India.*

Authors' contributions

This work was carried out in collaboration among all authors. Author SP designed the study, wrote the protocol and wrote the first draft of the manuscript. Author TVAK managed the analyses of the study. Authors AMA, BKAK, NM and AMP managed the literature searches. All authors read and approved the final manuscript.

Article Information

Editor(s):

(1) Dr. Maria Emilia Cosenza Andraus, Universidade Federal do Rio de Janeiro (UFRJ), Brazil.

Reviewers:

(1) Diego da Silva, Universitário Anchieta, Brazil.

(2) Sujan Narayan Agrawal, Late BRKM Government Medical College, India.

Complete Peer review History: <http://www.sdiarticle4.com/review-history/68110>

Short Communication

Received 25 February 2021

Accepted 02 May 2021

Published 11 May 2021

ABSTRACT

Subacute Sclerosing Panencephalitis (SSPE) is a progressive demyelinating disease of the central nervous system, associated with chronic infection of brain tissue with measles virus. Dykjan criteria for definite diagnosis of SSPE includes a) clinical features of declining cognition and myoclonus b) periodic discharges on EEG c) increased cerebrospinal fluid globulin levels d) elevated titers of anti-measles antibody and e) brain biopsy. Short term video EEG is a non invasive procedure with simultaneous EEG and video recording. EEG patterns in SSPE are characteristic and specific; which includes repetitive high amplitude paroxysmal polyphasic complexes with duration of 0.5-2 seconds and repetitive rate of 4-30 seconds. Short term video EEG is a useful diagnostic tool for confirming the diagnosis of SSPE. A simultaneous video recording will be helpful to documenting slow myoclonus and EEG correlation.

Keywords: SSPE; short term VEEG; periodic complexes.

**Corresponding author: E-mail: psajeesh@gmail.com;*

1. INTRODUCTION

Subacute Sclerosing Panencephalitis (SSPE) is a progressive demyelinating disease of the central nervous system; commonly seen in children and young adults [1]. Although it is a rare neurological disease associated with chronic infection of brain tissue with measles virus; often leads to fatal consequences [2]. Dykan SSPE diagnostic criteria includes a) clinical features of declining cognition and myoclonus b) periodic discharges on EEG c) increased cerebrospinal fluid globulin levels d) elevated titers of anti-measles antibody and e) brain biopsy [3]. Three or more criteria's are required for the diagnosis of definitive SSPE. EEG patterns in SSPE are characteristic and specific; which includes repetitive high amplitude paroxysmal polyphasic complexes with duration of 0.5-2 seconds and repetitive rate of 4-30 seconds [4]. However; EEG pattern alterations are documented in various stages of the disease [5].

2. CASE DESCRIPTION

A girl of 8 years old presented with the complaints of recurrent fall during walking, developmental regression and jerky movement of body for around 50 days. Parents gave the history of measles at Eighteen months of age. Initial MRI brain screening was normal. Short

term video EEG was done using Nicolet, USA. In addition; to the standard 10-20 system of electrode placement; surface EMG electrodes were also placed. Video recording was done in different positions to visualize the slow myoclonus. EEG showed classical long interval periodic complexes and simultaneous video recording showed 1:1 relation with slow myoclonus (Fig. 1). Clinical myoclonuses were disappeared during sleep and normal sleep rhythms were suppressed. The syndrome was identified simply because the procedure was in video EEG mode. For better visibility and identification of periodic complexes; change the conventional EEG paper speed of 30mm/second to 15 mm/second (Fig. 2).

Measles virus may persist in the central nervous systems and causes fatal neuro degenerative diseases like SSPE [6]. There is no remedial management for SSPE; most treatments are symptomatic interventions [7]. Atypical presentations are documented but still behavioral and intellectual changes followed by myoclonus and the so called Radermecker long interval periodic complexes are supportive in the diagnosis of SSPE [8]. In this case we could easily identify the classical long interval periodic complexes consists of generalized high voltage sharp and slow waves and slow myoclonus using the low cost non-invasive procedure; video EEG.

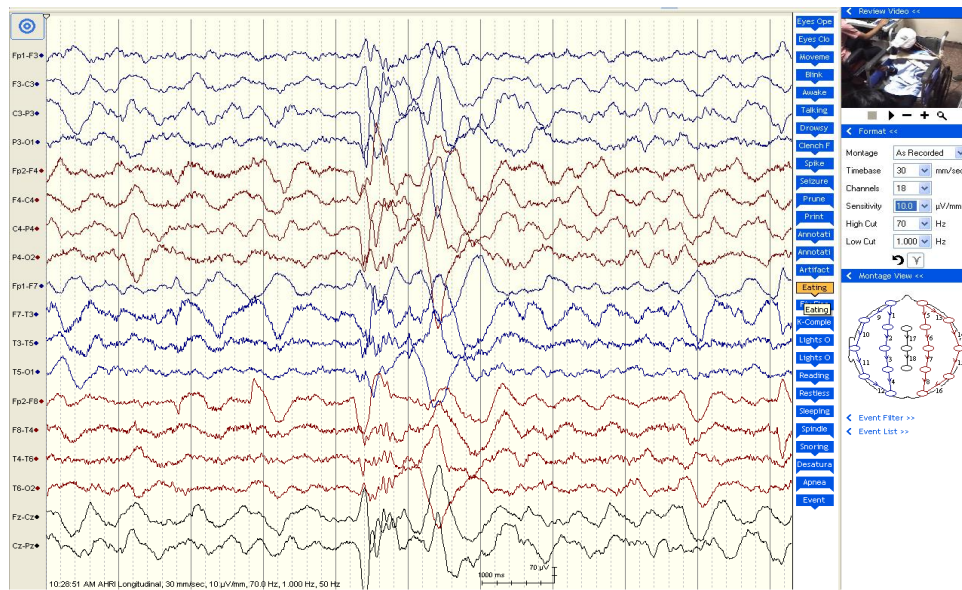


Fig. 1. EEG shows generalized sharp and slow wave complexes lasting about 1-2 seconds in conventional paper speed of 30mm/second

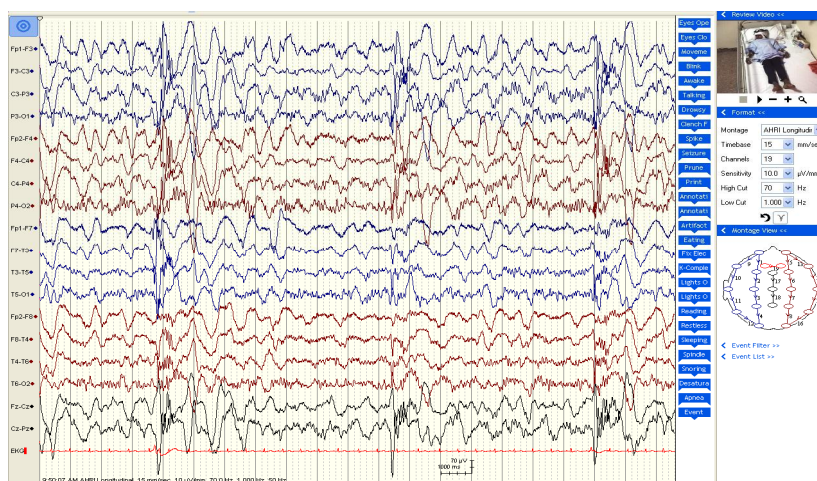


Fig. 2. EEG shows long interval periodic complexes at an interval of 5 seconds; EEG paper speed 15mm/second

3. CONCLUSION

Short term video EEG is a useful diagnostic tool for confirming the diagnosis of SSPE. A simultaneous video recording will be helpful to documenting slow myoclonus and EEG correlation.

CONSENT

It is not applicable.

ETHICAL APPROVAL

It is not applicable.

COMPETING INTERESTS

Authors have declared that no competing interests exist.

REFERENCES

1. Anlar B. Subacute sclerosing panencephalitis and chronic viral encephalitis. *Handb Clin Neurol.* 2013; 112:1183-9.
2. Abajirao SA, Nair M D, Kambale HJ. Subacute sclerosing panencephalitis: A clinical appraisal. *Ann Indian Acad Neurol.* 2013;16:631-3.
3. Dyken PR. Subacute sclerosing panencephalitis. *Current status. Neurol Clin.* 1985;3:179-96.
4. Praveen-Kumar S, Sinha S, Taly AB, Jayasree S, Ravi V, Vijayan J, Ravishankar S. Electroencephalographic and imaging profile in a subacute sclerosing panencephalitis (SSPE) cohort: a correlative study. *Clinical neurophysiology.* 2007;118(9):1947-54.
5. Gürses C, Öztürk A, Baykan B, Gökyiğit A, Eraksoy M, Barlas M, Calişkan A, Özcan H. Correlation between clinical stages and EEG findings of subacute sclerosing panencephalitis. *Clinical Electroencephalography.* 2000;31(4):201-6.
6. Watanabe S, Shirogane Y, Sato Y, Hashiguchi T, Yanagi Y. New insights into measles virus brain infections. *Trends Microbiol.* 2019;27:164-75.
7. Tatli B, Ekici B, Ozmen M. Current therapies and future perspectives in subacute sclerosing panencephalitis. *Expert Rev Neurother.* 2012;12:485-92.
8. Jafri S K, Kumar R, Ibrahim S H. Subacute Sclerosing panencephalitis-current perspective. *Pediatric health, medicine and therapeutics* 2018;9:67.

© 2021 Parameswaran et al.; This is an Open Access article distributed under the terms of the Creative Commons Attribution License (<http://creativecommons.org/licenses/by/4.0>), which permits unrestricted use, distribution, and reproduction in any medium, provided the original work is properly cited.

Peer-review history:
The peer review history for this paper can be accessed here:
<http://www.sdiarticle4.com/review-history/68110>