



Changes of Cardiac Rhythm after Closure of Secundum Atrial Septal Defect in Children

Esraa A. Sorour^{1*}, Elatafy E. Elatafy², Wael N. Lotfy³ and Amr M. Zoair¹

¹*Pediatric Department, Faculty of Medicine, Tanta University, Tanta, Egypt.*

²*Cardiothoracic Surgery Department, Faculty of Medicine, Tanta University, Tanta, Egypt.*

³*Pediatric Department, Faculty of Medicine, Cairo University, Cairo, Egypt.*

Authors' contributions

This work was carried out in collaboration among all authors. Author EAS designed the study, performed the statistical analysis, wrote the protocol and wrote the first draft of the manuscript. Authors EEE and WNL managed the analyses of the study. Author AMZ managed the literature searches. All authors read and approved the final manuscript.

Article Information

DOI: 10.9734/JAMMR/2020/v32i1030523

Editor(s):

(1) Chan-Min Liu, Xuzhou Normal University, PR China.

Reviewers:

(1) Irfanali Rajabali Kugasia, Baylor Scott and White Medical Centre, US.

(2) R. Vidhyapriya, PSG College of Technology, India.

(3) Mohamad Ayham Darwich, Al-Andalus University for Medical Sciences, Syria.

Complete Peer review History: <http://www.sdiarticle4.com/review-history/58832>

Original Research Article

Received 01 May 2020

Accepted 07 July 2020

Published 16 July 2020

ABSTRACT

Background: Arrhythmias may complicate congenital heart diseases, such as secundum atrial septal defects. We aimed at following up the rhythm changes in children after closure of ostiumsecundum atrial septal defects.

Methods: The current study was conducted in the Pediatric Cardiology Unit, Tanta University, on 60 pediatric patients who had undergone either trans-catheter or surgical closure of secundum atrial septal defects. Complete history taking and full clinical assessment were done. Echocardiographic assessment was performed to detect any residual defects, and assess chamber dimensions, and cardiac functions. Electrocardiographic assessment including Holter monitoring was performed within two months after the procedure, after six months, and after one year. Arrhythmias were classified into major and minor types. All results were statistically analyzed and tabulated.

Results: There were no significant differences between the pre-closure rhythm and the rhythm after closure of the defects throughout the follow-up. The percentage of patients with major arrhythmias

*Corresponding author: E-mail: esraa.fotouh@med.tanta.edu.eg;

has increased from 6.7% of the total sample to 13.3%, 11.6%, and 11.6% in the early, midterm and late follow up respectively. The significant risk factors for postoperative arrhythmias were; pre-closure arrhythmia, right atrial dilatation, and serious hemodynamic instability in the early follow up.

Conclusions: We concluded that arrhythmias were common before and after atrial septal defect closure, without significant differences. Pre-closure arrhythmia, right atrial dilatation, and serious hemodynamic instability are considered important risk factors of arrhythmias after secundum atrial septal defect's closure in pediatric patients.

Keywords: Arrhythmia; catheter; closure; secundum atrial septal defect; surgical.

1. INTRODUCTION

Atrial septal defects (ASD) are one of the most common congenital heart defects (CHD) [1]. The most common type of atrial septal defects is the secundum defect, located in the region of the fossa ovalis [2,3]. Closure of atrial septal defects is usually recommended when there is evidence of right sided chamber dilation [1]. Secundum atrial septal defect can be closed surgically or by transcatheter means [4,5].

After ASD closure, some patients have serious arrhythmias which may be a persistent preoperative arrhythmia, or a newly-developed arrhythmia [6]. Older patients are at the highest risk for such arrhythmias [7]. Local irritation from the procedure, the presence of occlusion devices or atriotomy scars in addition to the underlying substrate (due to remodeling), predispose those patients to such arrhythmias after atrial septal defect's closure [1].

After surgical closure of ASD, the most common arrhythmia in pediatrics is sinus node dysfunction manifested by ectopic atrial rhythms, bradycardia, or sick sinus syndrome; a few will eventually need pacemakers [6]. Paroxysmal or sustained atrial fibrillation are less common [6,8]. In adults, however, paroxysmal or sustained supraventricular tachycardia, atrial fibrillation or flutter are more common [6]. Post-surgical incisional re-entrant atrial tachycardia may occur; it can, however, be managed by ablation [9].

2.1 Inclusion and Exclusion Criteria

Inclusion criteria	Exclusion criteria
1. 18 years old or less.	1. Age more than 18 years old.
2. Children with a history of isolated ostium secundum ASDs corrected surgically or by transcatheter device closure	2. Other types of ASDs (ostium primum, sinus venosus) or any association with other significant forms of structural heart disease.
3. The procedure was done during or	3. Patients with any type of cardiomyopathy.

Electrocardiographic abnormalities reported after transcatheter closure are usually asymptomatic [10,11]. The most common reported arrhythmias are sinus bradycardia, premature atrial contraction, atrial flutter, Atrial fibrillation, supraventricular tachycardia, and atrioventricular block [11-15].

1.1 Rationale of Study

Arrhythmias were observed before or after closure of secundum ASD in many patients at our institution and at other similar institutions in Egypt. Some of these arrhythmias were life-threatening, e.g. permanent complete atrioventricular block, and symptomatic sinus node dysfunction. Therefore, this work aimed at following up the rhythm changes at different intervals after the closure of secundum ASDs, and determining the risk factors for the development of arrhythmias in such patients.

2. PATIENTS AND METHODS

This is a prospective study, conducted at the Pediatric Cardiology Unit, Tanta University, Egypt, in the period from December 2015 till December 2018, on 60 pediatric patients, who had undergone either transcatheter or surgical closure of secundum ASDs during the time of the study or within a few weeks prior to the study. The study was approved by the local ethical committee of our Faculty of Medicine.

Inclusion criteria	Exclusion criteria
within a few weeks before the time of the study.	
4. Patients whose previous clinical and electrocardiographic recordings were available.	4. Patients who had any form of permanent pacing before defect closure. 5. If patients had history of hepatic or renal failure or any metabolic disease that may be associated with arrhythmia

2.2 All patients were Subjected to

1. Complete history taking through paper charts, and collection of the previous echocardiographic and electrocardiographic data.
2. Full clinical assessment. including evaluation of blood pressure and other vital signs during different times of follow up.
3. Echocardiographic evaluation. An echocardiogram was performed for every patient repeatedly during the follow up. Patients were evaluated by GE Vivid7 Echocardiography ultrasound machine and S7, S5, S3 MHz probes (GE medical system, Horton, Norway). We followed the "American society for Echocardiography" recommendations in performing echocardiography for all patients [16]. We also followed the Guidelines of the Echocardiographic Assessment of Atrial Septal Defect and Patent Foramen Ovale of the American Society of Echocardiography for assessment of the atrial septal defect before and after the closure [17]. References for normal cardiac parameters were revised according to the published recommendations [18]. Chamber diameters were evaluated and correlated to the body surface areas, to determine if there was any chamber dilatation.

The right and left ventricular function were evaluated by following the recommendations of the "American Society of Echocardiography" [19-21].

4. Electrocardiographic evaluation. Twelve-lead electrocardiogram and 48-hours Holter evaluation were performed three times; immediately after the procedure, if possible, or within 2 months from the procedure (early follow up), at the sixth month after the procedure (mid-term follow up), and after one year from the procedure (late follow up).

We examined 12-lead ECG recordings using Cardico306 (SuzunkenKenz, Higashi-Ku, Nagoya, Japan); a real time electrocardiogram.

We evaluated the patients by a Holter device named: Biomedical Systems 300 (BMS 300), and Century Holter Analysis System C3000 software (Biomedical Systems, Louis, Belgium). The device had three channels. At the last four months of our study, we were obligated to use other Holter device and software because of a technical problem in the previous device. The other Holter device was Poly-Spectrum-AM recorder, and its software was the version 2.0.1.2 (Neurosoft Ltd, Ivanovo, Russia).

2.3 The Arrhythmias were Classified into

Minor arrhythmias	Major arrhythmias
Which did not need any intervention or close follow up	These arrhythmias required either intervention or close follow up.
Examples:	Examples:
1. Infrequent single supraventricular or ventricular ectopy	1. Sustained supraventricular or ventricular tachycardia.
2. Infrequent non-recurrent and non-sustained episodes of supraventricular or ventricular tachycardia that persisted for less than 30 seconds.	2. Atrial flutter and fibrillation.
3. Atrial or junctional escape rhythm.	3. Significant sinus node dysfunction as significant sustained sinus bradycardia, and sinus pause > 2.5 seconds.
4. Temporary atrioventricular block that occurred just during the surgery or device implantation.	4. Persistent atrioventricular block.

2.4 The Outcomes

1. The primary outcome was to follow up the pre-closure rhythm throughout different intervals as mentioned previously.
2. The secondary outcomes were to determine the risk factors for the development of arrhythmias after atrial septal defect's closure, and to describe different types of arrhythmias developed before or after the closure

2.5 Statistical Analysis

Statistical analysis was done using the SPSS 20.0 software package(SPSS Inc., Chicago, IL, USA, 2012).

Continuous (numerical) variables were summarized by the median and interquartile ranges, Categorical variables were expressed as percentages.

We used the Marginal homogeneity test to follow up the pre-closure rhythm throughout the different intervals.

We evaluated the different relative risk factors for the major arrhythmias by using Chi-Square, relative risk, 2x2 contingency table which provides the confidence interval and the odd ratio.

For all of the previous tests; the statistical significance was set at *P* valueless than 0.05[22].

3. RESULTS

The study included 60 patients who underwent secundum ASD repair (30 males and 30 females). Twenty-eight patients (46.7%) underwent surgical closure, 18 of them had surgical closure with patch, and the other 10 patients had direct surgical closure. The remaining 32 patients (53.3%) underwent catheter closure; using Amplatzer septal Occluder (AGA Medical, Golden Valley, MN, USA) in 20 of them, and Figulla–Occlutech Device(FOD; Occlutech, Jena, Germany) in the remaining 12.

The demographic and clinical data of the patients are summarized in Table 1.

The characters of atrial septal defects before the closure, as evaluated by echocardiography, regarding the size of the defect, and the sufficiency of the surrounding rims, are summarized in Table 2.

There were no significant changes in the pre-closure rhythm throughout the different intervals of follow up. There were 4 patients (6.7% of the total sample) who had major arrhythmias before their defects' closure; only one of them had

Table 1. Demographic and clinical data

Age (years)	
Median (Interquartile range)	5 (2.4- 7.3)
Minimum	1
Maximum	15
Body surface area (m²)	
Median (Interquartile range)	0.8 (0.45- 0.9)
Weight (Kg)	
Median (Interquartile range)	20 (11- 25)
Age > 6y (%)	26.7
Underweight (%) (According to the Egyptian growth charts)	43.3
Gender (%)	
Female/ Male	50/ 50
Family history of ASD (%)	16.7
Family history of congenital heart disease (%) (Ventricular septal defect (VSD))	6.7
Family history of arrhythmia (%)	6.7
Cardiac symptoms (%)	50.2
(Respiratory distress, recurrent pneumonia, Arrhythmia)	
Abnormal Cardiac examination (%) (Ejection systolic murmur on the pulmonary area)	43.8
Comorbidities (%) (Syndromes, Cerebral palsy, Skeletal deformities)	23.3
Type of procedure (%)Surgical/ Catheter	46.7/ 53.3

Table 2. Echocardiographic characters of the atrial septal defects

Size of the defect (mm)	
Median (Interquartile range)	14.5 (10-19)
Minimum	7
Maximum	30
More than one defect (%)	6.7
Atria septal aneurysm (%)	56.7
Deficient inferior vana cava rim (%)	6.7
Deficient superior vana cava rim (%)	10
Deficient AV rim (%)	6.7
Deficient superior rim (%)	6.7
Deficient Aortic rim (%)	60
Minor congenital anomaly (%) (Persistent left superior vena cava)	6.7
Abnormal mitral valve (%)	3.3

improved to a normal sinus rhythm at the sixth month of follow-up, and that improvement has persisted within the first year. However; there were 4 patients who developed new-onset major arrhythmias at the early follow up; one of them had improved to a normal sinus rhythm at 6 months, whereas a new patient had developed a major arrhythmia at the same time. There were no other rhythm changes recorded after the sixth months. The total percentage of patients with major arrhythmia before the closure increased from 6.7% of the total sample to 13.3%, 11.6%, 11.6% in the early, midterm and late follow up respectively (Table 3).

The significant risk factors of major arrhythmias were; pre-closure arrhythmias (in early, mid-term

and late follow up), right atrial dilatation (in mid-term follow up), and severe hemodynamic instability in the form of severe respiratory distress and a need for mechanical ventilation (in the early follow-up). Other factors that increased the risk of arrhythmias without significant statistics included; left atrial dilatation, left ventricular dilatation, right ventricular dilatation, and impaired right ventricular systolic and diastolic functions. The other factors including the type of the procedure, age, weight, size of ASD, sufficiency of rims, did not increase the risk of major arrhythmias (Table 4)

The major arrhythmias found in our patients, their onset, management, and outcome are summarized in Table 5.

Table 3. Follow up the pre-closure rhythm

Follow up of the rhythm		Rhythm pre-closure			Test	P_{value}
		Major arrhythmia	Minor arrhythmia	Normal		
Early follow up (Count) % within rhythm pre-closure	Major arrhythmia	(4) 100%	(0) 0.0%	(4) 8%	Marginal homogeneity test	0.275
	Minor arrhythmia	(0) 0.0%	(2) 33.3%	(1) 2%		
	Normal	(0) 0.0%	(4) 66.7%	(45) 90%		
6 th month (Count) % within rhythm pre-closure	Major arrhythmia	(3) 75%	(0) 0.0%	(4) 8%		0.695
	Minor arrhythmia	(0) 0.0%	(1) 16.7%	(1) 2%		
	Normal	(1) 25%	(5) 83.3%	(45) 90%		
1 year (Count) % within rhythm pre-closure	Major arrhythmia	(3) 75%	(0) 0.0%	(4) 8%		0.847
	Minor arrhythmia	(0) 0.0%	(0) 0.0%	(1) 2%		
	Normal	(1) 25%	(6) 100%	(45) 90%		

Table 4. Significant risk factors at different times of follow up

Follow up time	Risk factor	(N) Percentage in patients presented with arrhythmias	Odd ratio, relative risk	95% confidence value		P value
				Lower	Upper	
Early	Serious hemodynamic instability	(2) 22.2%	9.7, 9.7	4.5	20.6	0.016
	Pre-closure arrhythmia	(4) 44.4%	14, 14	5.4	36	0.001
Mid-term	Right atrium dilatation (6m)	(2) 28.6 %	11.6, 11.6	5.01	26.8	0.012
	Pre-closure arrhythmias	(3) 42.9%	39, 10.5	3.5	31.6	0.004
Late	Pre-closure arrhythmias	(3) 42.9%	39, 10.5	3.5	31.6	0.004

Table 5. Summary of the major arrhythmias

Type	Type of procedure	Onset	Outcome and management	
1	Sinus node dysfunction, slow atrial fibrillation, Atrioventricular node dysfunction	Surgical patch closure	Pre-closure	Permanent endocardial right ventricular pacemaker, Sotalol.
2	Sinus node dysfunction, slow atrial flutter, 2 nd degree 2:1 heart block	Figulla–Occlutech device closure	Pre- closure	Permanent endocardial right ventricular pacemaker.
3	Supraventricular tachycardia (AV reentry tachycardia)	Amplatzer device closure	Pre-closure	Arrhythmia recurred in immediate follow up controlled by amiodarone, which stopped after one year with close follow up of the patient.
4	Non sustained supraventricular tachycardia, events of Mobitz 1	Figulla–Occlutech device closure	Pre- closure	Follow up of the patient.
5	Complete heart block	Surgical patch closure	Early follow up after closure	Permanent endocardial right ventricular pacemaker.
6	Complete heart block	Surgical patch closure	Early follow up after closure	Permanent endocardial right ventricular pacemaker.
7	Complete heart block	Amplatzer device closure	Early follow up after closure, discovered at the 10 th day after the procedure	Permanent endocardial right ventricular pacemaker.
8	Supraventricular tachycardia (Ectopic Atrial tachycardia)	Surgical patch closure	Early follow up after closure	Amiodarone for six months, no recurrence.
9	Sinus node dysfunction	Amplatzer device closure	6 th month follow up	Follow up of the patient.

Three patients developed complete heart block early after the procedure; two of them were discovered about one month after surgical closure (cases number 5 and 6 in Table 5). The

other one was discovered ten days after implantation of a 22mm Amplatzer ASD device (case number 7 in Table 5), (Fig. 1). Those patients were aged 18 months, 2 years, and 5 years, and their defects' sizes were 13.3, 22. 20 mm, respectively. The three patients needed permanent endocardial right ventricular pacemaker implantation (Medtronic Inc., Minneapolis, Minnesota).

Another patient, aged one year, whose 18 mm ASD was closed surgically, had developed eventration of the diaphragm and supraventricular tachycardia (ectopic atrial tachycardia), which discovered one week after the procedure. Her arrhythmia was controlled by antiarrhythmic medication and we managed to stop the antiarrhythmic medication after one year of follow up without recurrence (case number 8 in Table 5), (Fig. 2).

In addition, there was one patient, aged 6 years, with a 19-mm- ASD, who developed a sinus node dysfunction in the sixth month, after the implantation of 22mm Amplatzer device. This patient had Holt-Oram syndrome and a family history of atrial septal defect, skeletal anomalies, and a sudden unexplained cardiac death in her brother. We closely followed up the patient and decided to refer her for genetic study but unfortunately, we lost her to follow up after one year (case number 9 in Table 5).

Regarding pre-closure arrhythmia, it has improved only in one patient who had supraventricular tachycardia (atrioventricular reentry tachycardia). It recurred only once at the early follow up after ASDclosure with Amplatzer device. The patient had severe respiratory

distress and pneumonia which necessitated mechanical ventilation during this single event of recurrence (case number 3 in Table 5).

Another patient, aged 9 years at correction, with a secundumASDmeasuring 14mm, had sinus node and atrioventricular node dysfunction before intervention. He had atrial fibrillation with slow ventricular rhythm, most of the time, and infrequent non sustained episodes of rapid atrial fibrillation. Sinus rhythm was reported infrequently with a 1st degree heart block. We tried to restore sinus rhythm before atrial septal defect closure bysynchronizing external directcurrent cardioversion after the administration of anticoagulants, but we failed. The rhythm was notrestored after surgicalclosure ofthe ASD. The clinical condition of the patient became worse and he had two attacks of syncope, so a permanent right ventricular endocardial pacemaker was implanted (Medtronic Inc., Minneapolis, Minnesota).We kept the patient on oral anticoagulants and antiarrhythmic to control the atrial fibrillation(case number 1 in Table 5).

Another patient, 8 years old, with a 9-mm secundumASD,also had a pre-closure arrhythmia in the form of sinus node dysfunction, and events of slow atrial flutter with high degree atrioventricular nodal block (AVNB).His ASD was managed by a 12-mm FigullaOcculetech device. His rhythm had worsened, and he had developed a 2nd degree 2:1 AVNB and necessitated a permanent right ventricular endocardial pacemaker (Medtronic Inc., Minneapolis, Minnesota) (case number 2 in Table 5).

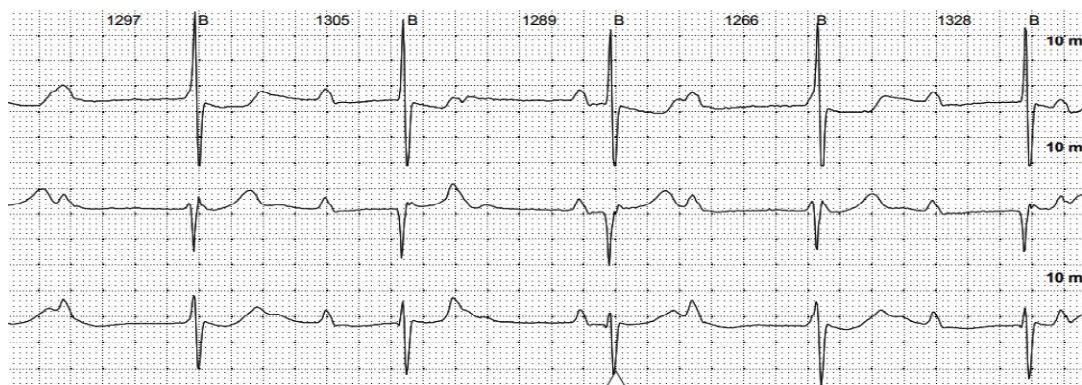


Fig. 1. Electrocardiogram for case number 7 in Table 5

Holter strip showed complete heart block in the patient after Amplatzer ASD's device implantation, in the early follow up

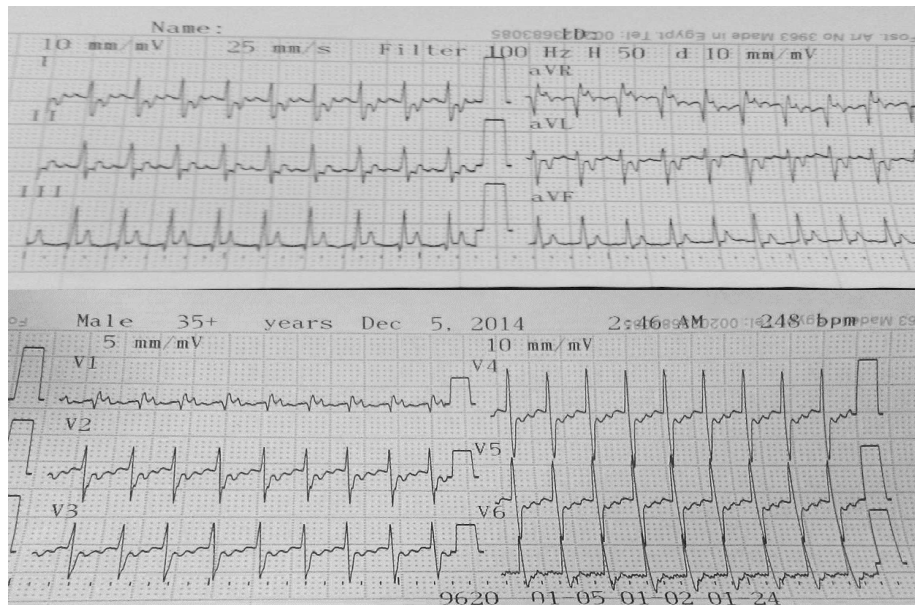


Fig. 2. Electrocardiogram for case number 8 in Table 5
 12 lead ECG showed Ectopic Atrial tachycardia after surgical closure of ASD in the early follow-up

Another patient, aged 16 years at the time of her 11-mm ASD's closure with 15mm Figulla device, had recurrent short runs of supraventricular tachycardia before the closure. The longest recorded event was 5 minutes. She had also recorded short events of Wenckebach phenomenon. Her arrhythmia persisted after the procedure, but without significant symptoms, so we just followed her closely (case number 4 in Table 5).

In our patients, minor arrhythmias were mainly reported pre-closure and improved after the closure. There was transient heart block during device implantation, infrequent supraventricular and ventricular ectopies, atrial escape rhythm, and junctional escape rhythm (Table 3).

4. DISCUSSION

Secundum atrial septal defect is one of the most common types of CHD [23]. It is often treated with surgery or device closure procedures [13]. The current aim of atrial septal defect treatment is to abolish the intra-cardiac shunt and incidence of complications or comorbidities [24]. Arrhythmias after ASD's repair are frequent and have prognostic implications [13].

This is a prospective study that followed rhythm changes after secundum atrial septal defect's closure through three different intervals. The early follow up was done immediately or within 2 months after the procedure, which is the time influenced by acute circumstances during the procedure. The mid-term follow-up was done six months after the procedure, which is the expected time for the mechanical and functional improvement of the heart. The late term follow-up was done one year after the procedure to investigate late-onset or persistent arrhythmias.

We could not find significant changes from the pre-closure rhythm throughout the follow up. In addition, we could not find significant relations between major arrhythmias and the age of patients at the time of closure, patients' weight, type of the procedure, size of the defects, and sufficiency of the rims. However, the significant predictors of arrhythmias were the pre-closure arrhythmias, clinical deterioration at the early follow up in the form of severe respiratory distress that necessitated mechanical ventilation, and right atrial dilatation that increased the risk of arrhythmias at the sixth month. Dilated left atrium and left ventricle, dilated right ventricle, impaired right ventricular systolic and diastolic functions, increased the risk for arrhythmias without

significant statistics which may be attributed to the small sample size.

Although no significant relation was found between patients' arrhythmias and their family history of atrial septal defects or arrhythmias; we had two patients with familial atrial septal defect who had sinus node dysfunction. One of them has history of sudden unexplained death of her brother with secundum atrial septal defect one week after ASD closure.

Although rim deficiency could not be proved as a significant risk factor in our cases, we have two patients with flimsy rims, one with flimsy atrioventricular rim who developed complete heart block after Amplatzer device implantation, the other with flimsy superior vena cava rim who developed sinus node dysfunction after Amplatzer device implantation as well.

In our cases, there were three patients with skeletal abnormalities. Two of them were siblings with skeletal deformities in hands and feet, these ASDs were closed via direct surgical closure. The third patient had Holt-Oram syndrome with a device-closed atrial septal defect. Her brother had the same problem (Holt-Oram syndrome and secundum atrial septal defect), and died suddenly one week after his atrial septal defect closure. These findings confirmed the recommendations from other studies that patients with musculoskeletal limb malformations and their first-degree relatives, should always be screened for accompanying congenital heart diseases, especially ASDs. Again, patients with atrial septal defect, particularly in association with a hereditary syndrome should be examined for any musculoskeletal defects [25].

We lost one patient from our study during his early follow up. He was 11 months at the time of correction, and had a secundum atrial septal defect measuring 24mm. His mean pulmonary artery pressure was 85mmHg. There were associated right atrial and ventricular dilatations, and left atrial dilatation. Before atrial septal defect closure, the patient developed an attack of atrial flutter with heart failure which was controlled with external synchronizing direct current cardioversion. Then, the patient received amiodarone. Diagnostic catheterization was done and revealed that the patient was operable. Surgical closure of the atrial septal defect was done. The patient died after five days due to

severe pulmonary hypertension. This patient raised our attention towards the association between heritable ASD and primary pulmonary hypertension due to possible genetic mutations.

In our study; the percentage of patients with major arrhythmias has increased from 6.7% of the total sample before the defect closure, to 13.3%, 11.6%, 11.6% in the early, midterm and late follow-up, respectively. That was different from the findings of Oliver et al [26], who studied the fate of atrial fibrillation in adult patients with secundum ASDs after closure of the defects. They found that the incidence decreased to 13.8% after closure, versus 15.6% before closure.

Kutty and coworkers [27] also compared two groups of patients treated surgically and by device closure. The researchers found a similar incidence of arrhythmias (9.8%) at 20-years of follow-up.

As compared to our study; the arrhythmias reported by Castaldi et al [24] were mainly minor in the form of frequent and infrequent supraventricular and ventricular ectopies. There was a low incidence of supraventricular couplets or runs. They reported asymptomatic nocturnal atrioventricular blocks in patients treated with Gore device. As in our study, they could not find a relation between arrhythmias, device size and age at correction. As compared to us, they could not confirm a relation between arrhythmia and any echocardiographic variables.

Comparing to our study, Du et al [28], in their study on pediatric and adult population, compared the electrocardiographic findings post closure in both procedures. They reported major cardiac arrhythmias in two patients of the device group, whereas no major cardiac arrhythmias in the surgical group. They also reported minor cardiac arrhythmias in both groups. The major cardiac arrhythmias reported by them were complete atrioventricular block that was found at the sixth month, in a 6-year old girl with 11-mm ASD and aneurysm of the atrial septum. This patient necessitated permanent cardiac pacemaker. Atrial fibrillation occurred in an 81-year-old patient requiring antiarrhythmic medication.

Wilson et al [29] performed a retrospective study on adults and children who underwent

transcatheter closure of secundum ASD to review the complications including arrhythmia. Pre-existing arrhythmias were documented in 26 patients. The later were in the form of atrial fibrillation/atrial flutter, supraventricular tachycardia, atrial tachycardia, long QT syndrome, frequent ectopy and ablated arrhythmias with atrioventricular nodal reentry tachycardia (AVNRT) and Wolf Parkinson White syndrome (WPW). All patients with arrhythmias were adults except for a 5-year-old with long QT syndrome. Arrhythmias in the form of atrial fibrillation or atrial tachycardia persisted in ten patients while new arrhythmias occurred in six (3%) of patients, and symptoms persisted beyond three months in four patients. Treatment was successful either with anti-arrhythmic medication alone, radio frequency ablation or cardioversion and there was one patient awaited treatment.

The previous findings by Du et al [28], and Wilson et al [29] confirmed that atrial fibrillation with ASD or after its closure is more common in older age. Although our study did not include adult patients, the only patient who had atrial fibrillation (associated with sinus node dysfunction) in our study was a 9-year old child at the time of the atrial septal defect closure.

Our study, like others, reported that sinus node dysfunction may complicate ASD closure. Hudic et al [30] also reported a case report of 38-year female presented with syncope and sinus node dysfunction after surgical Patch closure of ASD. That is different from our case who developed asymptomatic sinus node dysfunction after Amplatzer atrial septal defect closure.

Similar to our findings; other studies proved that complete heart block may complicate ASD closure. This complication may be transient and resolves spontaneously [27,31-33]. It may require re-intervention as in the study reported by Clark et al [34]. Despite it is rare, complete heart block may be permanent and require permanent cardiac pacemaker as in our study and other series [28,35]. However, we reported higher number of patients with complete heart block after ASD closure. That may be explained by technical problems in the procedure, as in the patient who underwent Amplatzer device closure despite flimsy atrioventricular rim. The heart block in this patient was discovered at the tenth day after the procedure, so the decision for device removal was not taken.

In contrary to our results; some other studies, e.g. Rossi et al [36], and Pedra et al [37], could not find any significant arrhythmias after atrial septal defect's closure. The arrhythmias reported by Hessling et al [12] were rare and benign. Chen et al [38], and Ali et al [39] reported transient arrhythmias after device closure of ASD which were easily treated by medication or resolved spontaneously.

Similar to our study; Silversides et al [40] studied the predictors of atrial arrhythmias after device closure of atrial septal defect. They found that the prevalence of atrial tachycardia increased in patients with history of paroxysmal atrial tachycardia compared with those with no history of atrial tachycardia. They also found that echocardiographic changes, such as atrial remodeling, after the closure, may be predictors of late arrhythmic events.

Chiu et al [41] in their study on adult population who closed secundum ASD by devices, agreed about the relation between pre-closure arrhythmia and postoperative rhythm disorders. In contrary to us, they found that the age of closure, size of the device (which corresponded to the size of the defect), presence of multiple defects, and underlying disorders (thyroid or mitral valve disorder) were the most important risk factors for the development of arrhythmias after closure.

In contrary to our study; deficient rims were significant risk factors of production of arrhythmia in some other studies conducted on patients with transcatheter closure of ASD [42,43].

Jin et al [13] suggested that the ratio of the atrial septal occluder to the atrial septal length was considered a risk factor for the development of arrhythmia after secundum ASD's device closure in pediatrics. In contrary; we could not relate the size of the devices as a risk factor due to the limited number of our patients.

In contrary to our study, the study of Ili et al [44] was keen about highlighting the importance of management of arrhythmias prior to atrial septal defect closure. They found that a bi-atrial surgical ablation led to an improved electrophysiological outcome in atrial fibrillation associated with atrial septal defect.

The main limitation of our study was the small number of patients. As we were worried about statistical errors and inaccurate results; we could not divide this small sample into two groups to compare the incidence of arrhythmias between surgical and device closure. However, we estimated the type of procedure as a risk factor. Finally, longer follow-up period was required for better assessment of the late onset arrhythmia.

We recommend conducting studies with prolonged durations of follow-up for proper assessment of late onset arrhythmias, and multicenter studies about arrhythmias after ASD closure, to allow exchange of experience and overcome risk factors. We also recommend conducting more genetic studies and screening for familial ASD to diagnose the risks for malignant arrhythmias in such patients, and perform the proper prophylaxis.

5. CONCLUSION

There were no significant changes in the cardiac rhythm after secundum ASD's closure.

Significant arrhythmias as sinus node dysfunction and complete heart block may occur before or after secundum ASD's closure and may require pacemaker implantation. Other significant arrhythmias associated with secundum atrial septal defect are supraventricular tachycardia (atrioventricular reentry and ectopic atrial tachycardia), atrial flutter, and atrial fibrillation.

Pre-closure sinus node dysfunction, prolonged atrial fibrillation, and atrioventricular node dysfunction may not be improved after ASD's closure, whereas supraventricular tachycardia may be improved.

The risk factors which were associated with the development of post-intervention or post-operative arrhythmias include: pre-closure arrhythmias, right atrial dilatation, in addition to the clinical circumstances that affect the hemodynamics of the patient after the procedure which have a relation with the early-onset arrhythmias in those pediatric patients.

CONSENT

Written Informed consent was signed by the parents or caregivers.

ETHICAL APPROVAL

The study is in accordance with the ethical standards of institutional research committee and with the 1964 Helsinki declaration and its later amendments.

COMPETING INTERESTS

Authors have declared that no competing interests exist.

REFERENCES

1. Contractor T, Ravi MR. Arrhythmias in Patients with Atrial Defects. *Card Electrophysiol Clin.* 2017;9(2):235–244.
2. Sachdeva R. Atrial Septal Defects. In: Allen HD, Shaddy RE, Penny DJ, et al, eds. *Moss and Adams' heart disease in infants, children, and adolescents: including the fetus and young adult*, volume one, 9th edn. Philadelphia: Lippincott Williams and Wilkins. 2016;740-757.
3. Geva T. Anomalies of the atrial septum. In: Lai WW, Mertens LL, Cohen MS, et al, eds. *Echocardiography in Pediatric and Congenital Heart Disease: From Fetus to Adult*, 2nd edn. Chichester, Hoboken: Wiley-Blackwell. 2016;159-174.
4. Pedra CA, Pedra SR. Atrial level shunts including partial anomalous pulmonary venous connection and scimitar syndrome. In: Moller JH and Hoffman JI, eds. *Pediatric Cardiovascular Medicine*, 2nd edn. Oxford: Blackwell. 2012;289-307.
5. Lowery KS. Atrial Septal Defects. *Physician Assist Clin.* 2016;1:553–562.
6. Hoffman JI. Atrial septal defect (secundum). In: Hoffman JI, ed. *The natural and unnatural history of congenital heart disease*. Oxford: Blackwell. 2009;133–156.
7. Duong P, Ferguson LP, Lord S, et al. Atrial arrhythmia after transcatheter closure of secundum atrial septal defects in patients ≥ 40 years of age. *Europace.* 2017;19(8):1322–1326.
8. Murphy JG, Gersh BJ, McGoon DC. Long-term outcome after surgical repair of isolated atrial septal defect: follow-up at 27 to 32 years. *N Engl J Med.* 1990;323:1645–1650.

9. Johnson JN, Marquardt ML, Ackerman MJ, et al. Electrocardiographic Changes and Arrhythmias Following Percutaneous Atrial Septal Defect and Patent Foramen Ovale Device Closure. *Catheter CardiovascInterv.* 2011;78(2):254–261.
10. Celiker A, Ozkutlu S, Karakurt C, et al. Cardiac dysrhythmias after transcatheter closure of ASD with Amplatzer device. *Turk J Pediatr.* 2005;47:323–326.
11. Lin SM, Hwang HK, Chen MR. Amplatzer septal occluder-INDUCED transient complete atrioventricular block. *J Formos Med Assoc.* 2007;106(12):1052–1056.
12. Hessling G, Hyca S, Brockmeier K, et al. Cardiac dysrhythmias in pediatric patients before and 1 year after transcatheter closure of atrial septal defects using the amplatzer septal occluder. *Pediatric Cardiology.* 2003;24(3):259–262.
13. Jin M, Ding WH, Wang XF, et al. Value of the ratio of occluder versus atrial septal length for predicting arrhythmia occurrence after transcatheter closure in children with ostium secundum atrial septal Defect. *Chin Med J.* 2015;128:1574–1578.
14. Komar M, Przewlocki T, Olszowska M, et al. Conduction abnormality and arrhythmia after transcatheter closure of atrial septal defect. *Circ J.* 2014;78:2415–2421.
15. Knepp MD, Rocchini AP, Lloyd TR, et al. Long-term follow up of secundum atrial septal defect closure with the amplatzer septal occluder. *Congenit Heart Dis.* 2010;5:32–37.
16. Lopez L, Colan SD, Frommelt PC, et al. Recommendations for quantification methods during the performance of a pediatric echocardiogram: a report from the Pediatric Measurements Writing Group of the American Society of Echocardiography Pediatric and Congenital Heart Disease Council. *J Am SocEchocardiogr.* 2010;23:465-495.
17. Silvestry FE, Cohen MS, Armsby LB, et al. Guidelines for the echocardiographic assessment of atrial septal defect and patent foramen ovale: from the American Society of Echocardiography and Society for Cardiac Angiography and Interventions. *J Am SocEchocardiogr.* 2015;28:910–958.
18. Cantinotti M, Scalese M, Murzi B, et al. Echocardiographic Nomograms for Chamber Diameters and Areas in Caucasian Children. *J Am SocEchocardiogr.* 2014;27(12):1279–1292.
19. Lang RM, Bierig M, Devereux RB, et al. Recommendations for chamber quantification. *J Am SocEchocardiogr.* 2005;18:1440–1463.
20. Nagueh SF, Smiseth OA, Appleton CP, et al. Recommendations for the evaluation of left ventricular diastolic function by echocardiography: An update from the american society of echocardiography and the european association of cardiovascular imaging. *J Am SocEchocardiogr.* 2016;29:277-314.
21. Rudski LG, Lai WW, Afilalo J, et al. Guidelines for the echocardiographic assessment of the right heart in adults: a report from the American Society of Echocardiography. *J Am SocEchocardiogr.* 2010;23:685–713.
22. Galie N, Humbert M, Vachiery J, et al. 2015 ESC/ERS Guidelines for the diagnosis and treatment of pulmonary hypertension. *European Heart J.* 2016;37:67-119.
23. Kazmouz S, Kenny D, Cao Q, et al. Transcatheter Closure of Secundum Atrial Septal Defects. *J Invasive Cardiol.* 2013;25(5):257-264.
24. Castaldi B, Vida VL, Argiolas A, et al. Late Electrical and mechanical remodeling after atrial septal defect closure in children: Surgical versus percutaneous approach. *Ann Thorac Surg.* 2015;100:181–186.
25. Siniorkakis E, Arvanitakis S, Tzevelekos P, et al. Brachydactyly and atrial septal defect: When the digits point to the heart. *International Journal of Cardiology.* 2014;177:90–92.
26. Oliver JM, Gallego P, Gonzalez A, et al. Predisposing conditions for atrial fibrillation in atrial septal defect with and without operative closure. *Am J Cardiol.* 2002;89:39–43.
27. Kutty S, Hazeem AA, Brown K, et al. Long-term (5- to 20- year) outcomes after transcatheter or surgical treatment of hemodynamically significant isolated secundum atrial septal defect. *Am J Cardiol.* 2012;109:1348–1352.
28. Du ZD, Hijazi ZM, Kleinman CS, et al. Comparison between transcatheter and surgical closure of secundum atrial septal defects in children and adults: results of a

- multicenter non randomized trial. *J Am CollCardiol.* 2002;39(11):1836-1844.
29. Wilson NJ, Smith J, Prommete B, et al. Transcatheter closure of secundum atrial septal defects with the amplatzer septal occluder in adults and children—follow-up Closure Rates, Degree of Mitral Regurgitation and Evolution of Arrhythmias. *Heart, Lung and Circulation.* 2008;17:318–324.
 30. Hudic LD, Kusljagic Z, Bijedic I, et al. Syncope due to sinus node dysfunction after surgical patch closure of atrial septal defect – A Case Report. *Medicinski pregled.* 2017;70(5-6):167-169.
 31. Chen Q, Cao H, Zhang GC, et al. Atrioventricular block subsequent to intraoperative device closure atrial septal defect with transthoracic minimal invasion; A rare and serious complication. *PLoS ONE.* 2012;7(12):52726.
 32. Rohit MK, Puri K, Vadivelu R. Reversible complete atrioventricular block after percutaneous ASD device closure in a child <15 kg. *Indian heart journal.* 2014;66:366 -369.
 33. Al Akhfash AA, Al-Mesned A, Fayadh MA. Amplatzer septal occluder and atrioventricular block: A case report and literature review. *J Saudi Heart Assoc.* 2013;25:91–94.
 34. Clark JB, Chowdhury D, Pauliks LB, et al. Resolution of heart block after surgical removal of an amplatzer device. *Ann Thorac Surg.* 2010;89:1631–1633.
 35. Dittrich S, Sigler M, Priessmann H. Late Complete Atrioventricular Block After Closure of an Atrial Septal Defect with a Gore Septal Occluder (GSOTM). *Catheter CardiovascInterv.* 2016;87:945–950.
 36. Rossi RI, Cardoso CD, Machado PR, et al. Transcatheter closure of atrial septal defect with amplatzer device in children aged less than 10 years old: Immediate and late follow-up. catheterization and cardiovascular interventions. 2008;71:231–236.
 37. Pedra CA, Pedra IF, Costa RN. Mid-Term Outcomes after percutaneous closure of the secundum atrial septal defect with the figulla-occlutech device. *J IntervenCardiol.* 2016;29:208–215.
 38. Chen Q, Cao H, Zhang G MD, et al. Short-term and midterm follow-up of transthoracic device closure of atrial Septal defect in infants. *Ann Thorac Surg.* 2017;104(4):1403-1409.
 39. Ali SH, El Sisi A, Duaa M, et al. Short-term outcomes of transcatheter closure of secundum atrial septal defect in children and adolescents: An experience of two centers in Upper Egypt. *J Saudi Heart Assoc.* 2018;30:14-20.
 40. Silversides CK, Haberer K, Siu SC, et al. Predictors of Atrial Arrhythmias After Device Closure of Secundum Type Atrial Septal Defects in Adults. *Am J Cardiol.* 2008;101:683–687.
 41. Chiu SN, Wu MH, Tsai CT, et al. Atrial flutter/fibrillation in patients receiving transcatheter closure of atrial septal defect. *Journal of the Formosan Medical Association.* 2017;116:522-528.
 42. Kannan BR, Francis E, Sivakumar K, et al. Transcatheter closure of very large (>or= 25mm) atrial septal defects using the Amplatzer septal occluder. *Catheter CardiovascInterv.* 2003;59:522–527.
 43. Park KM, Hwang JK, Chun KJ, et al. Prediction of early-onset atrial tachyarrhythmia after successful transcatheter device closure of atrial septal defect. *Medicine.* 2016;95(35):4706.
 44. Im YM, Kim JB, Yun SC, et al. Arrhythmia surgery for atrial fibrillation associated with atrial septa defect: Right-sided maze versus biatrial maze. *J ThoracCardiovasc Surg.* 2013;145:648–655.

© 2020 Sorour et al.; This is an Open Access article distributed under the terms of the Creative Commons Attribution License (<http://creativecommons.org/licenses/by/4.0>), which permits unrestricted use, distribution, and reproduction in any medium, provided the original work is properly cited.

Peer-review history:

The peer review history for this paper can be accessed here:
<http://www.sdiarticle4.com/review-history/58832>