



An Interesting Case of Spingobacterium Multivorum Neck Abscess

Muhammad Khalid^{1*}, Imran Khan², Arsalan Hashmi³, Majd Kanaa¹, Paul Lewis⁴ and Paras Patel²

¹Internal Medicine Resident, East Tennessee State University, Quillen College of Medicine, USA.

²Department of Medicine, Division of Infectious Disease, East Tennessee State University, Quillen College of Medicine, USA.

³Internal Medicine Resident, Maimonides Medical Center, USA.

⁴Ballard Health, Mountain States Health Alliance, USA.

Authors' contributions

This work was carried out in collaboration between all authors. Author MK developed the idea presented in article and wrote the first draft of the manuscript. Authors IK, AH and MK did literature review, completed the discussion part and references. Author PL reviewed the literature about antibiotics sensitivity and resistance. Author PP managed the final review and approval before final submission. All authors read and approved the final manuscript

Article Information

DOI: 10.9734/AJRID/2018/11113941

Editor(s):

(1) Hetal Pandya, Professor, Department of Medicine, SBKS Medical Institute & Research Center-Sumandeep Vidyapeeth, Vadodara, Gujarat, India.

Reviewers:

(1) Jorge Roig, Spain.

(2) Maria Antonietta Toscano, University of Catania, Italy.

Complete Peer review History: <http://www.sciencedomain.org/review-history/24984>

Case Study

Received 25th March 2018

Accepted 31st May 2018

Published 5th June 2018

ABSTRACT

Soft tissue infections due to gram negative microorganism are very rare. Spingobacterium multivorum related respiratory tract infections, cellulitis, necrotizing fasciitis and septic shock have been reported in literature mostly in immunosuppressed population. We present an interesting and rare case of neck abscess due to spingobacterium multivorum in an immunocompetent patient, diagnosed by abscess fluid culture and neck imaging and treated with course of oral antibiotics.

Keywords: *Spingobacterium; abscess; poor oral hygiene.*

1. INTRODUCTION

Sphingobacterium species are catalase and oxidase positive, non- lactose fermenting gram-negative organisms characterized by presence of large number of cell membrane sphingophospholipids. Sphingobacterium species are ubiquitous and isolated from natural environment such as soil and water. Only limited number of cases have been reported in the literature about sphingobacterium associated chronic respiratory tract infections, cellulitis, necrotizing fasciitis, septic shock in the elderly and immunocompromised patients with underlying comorbidities and predisposing factors. We present a case of 35 years old fairly healthy male with neck abscess due to sphingobacterium multivorum.

2. CASE DESCRIPTION

35 years old caucasian male with ongoing smoking and past medical history of hepatitis C infection and gastroesophageal reflux disease presented at an outside hospital with complaints of sudden onset of sore throat for one day which was associated with dysphagia. He denied fever, chills, cough, night sweats, weight loss, appetite changes, nausea, vomiting, diarrhea, constipation, shortness of breath, facial pain, muscle aches, joint pain, skin rash, headache and any sick contacts. On admission, vital signs were normal. Physical examination was significant for 2 x 3 cm mobile tender and ballotable anterior neck swelling over the thyroid cartilage with no redness of the overlying skin, no ulceration and discharge. Patient had poor dental hygiene but no oral thrush or ulcers. Laboratory workup showed normal blood counts, kidney and liver functions. Computed tomography scan of the soft tissue neck revealed multiloculated fluid collections of 1.7 x 3.0 cm in the anterior neck

extending into the vallecula and piriform sinus on the left [Fig. 1]. Patient was transferred to our hospital and started on pip/taz and vancomycin empirically. Patient initially had improvement in sore throat and neck pain after aspiration of 7 ml of dark brown fluid from the neck mass. Patient had swelling of aryepiglottic fold and complete obliteration of left of piriform sinus on flexible laryngoscopy performed by ENT. Repeat CT neck soft tissue showed minimal interval enlargement of superinfected thyroglossal duct cyst with adjacent soft tissue edema and moderate airway narrowing from prior examination with high risk of laryngospasm [Fig. 2 and 3]. Patient was taken emergently to the operation theater for direct laryngoscopy and needle aspiration of another 8 ml of dark brown fluid from bilobed infected neck cyst was performed and fluid was set up for aerobic and anaerobic cultures. Gram stain was negative initially but MacConkey agar in 36 hours showed growth of sphingobacterium at incubation of 37°C. It was found to be catalase and oxidase positive and non lactose fermentative. Isolate of sphingobacterium multivorum was identified using the VITEK II system. Antibiotics susceptibility testing was done using same VITEK II system for 15 antibiotics and it was susceptible to ceftriaxone (MIC 8 µg/ml), cefazolin (MIC 8 µg/ml), imipenem (1 µg/ml), meropenem (4 µg/ml), levofloxacin (< 0.12 µg/ml), tetracycline (2 µg/ml) and trimethoprim-sulfamethoxazole (< 20 µg/ml). It was resistant to ampicillin, amikacin, gentamicin, tobramycin, cefuroxime and cefuroxime-Axetil, It had intermediate susceptibility to amoxicillin /clavulanate and piperacillin /tazobactam. Based upon susceptibility results, antibiotics were switched to oral levofloxacin 500 mg twice daily along with oral clindamycin 300 mg three times a day for 14 days and patient was discharged from hospital on clinical improvement. On follow up in

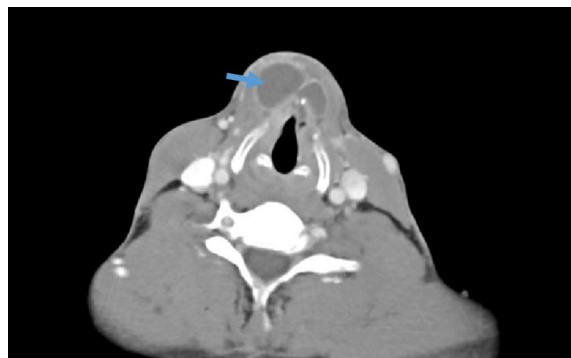

Fig. 1. Computed tomography of soft tissue neck revealed multiloculated fluid collections 1.7 x 3.0 cm [Arrow]

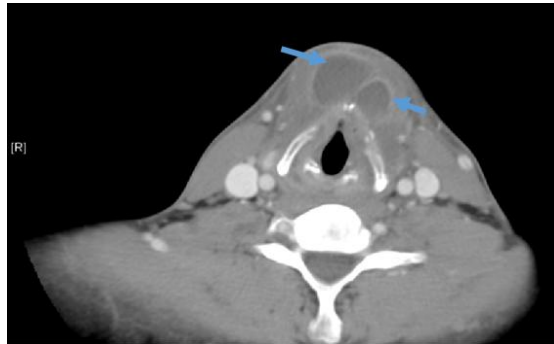


Fig. 2. Repeat CT neck soft tissue showed minimal interval enlargement of neck abscess [Arrows]

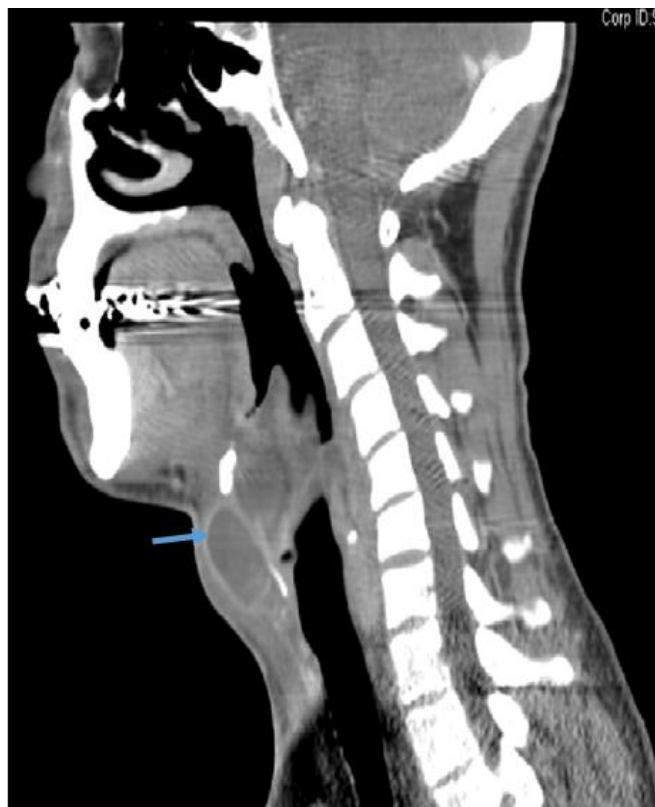

Fig. 3. Repeat CT neck soft tissue showed minimal interval enlargement of abscess [Arrow]

infectious disease clinic in 2 weeks patient had resolution of neck swelling and associated symptoms.

3. DISCUSSION

Soft tissue neck infections are usually polymicrobial commonly originating from the normal mucosal flora of surrounding structures including oral cavity, mandibular teeth, tonsils, parotid glands, deep cervical lymph nodes,

middle ear cavity or sinuses and upper respiratory tract. The most common microorganisms isolated are streptococcus viridans and anaerobes including peptostreptococcus species, fusobacterium nucleatum, prevotella species such as prevotella melaninogenica and actinomyces species. Gram-negative deep neck soft tissue infections including those secondary to sphingobacterium species are very rare. The genus Sphingobacterium consists of six species

including sphingobacterium spiritovorum, sphingobacterium multivorum, sphingobacterium mizutaii, sphingobacterium antarcticum, sphingobacterium faecium and sphingobacterium thalophilum. An important characteristic of this genus is the presence of abundant sphingolipids in the cellular lipid membranes hence the name sphingobacterium [1]. Sphingobacterium multivorum is a catalase and oxidase positive, gram negative, non-lactose fermentative microorganism. They are ubiquitous in nature and rarely cause infections in humans. Sphingobacterium species have the ability to survive in moist hospital environments and also can contaminate laboratory culture media. It was thought to be primarily related to opportunistic infections in HIV population and later was considered as a triggering factor for sepsis and death in that population.

There are only few cases of human infections due to sphingobacterium multivorum which are reported in the literature mostly in elderly population with multiple co-morbidities and in immunocompromised hosts and include cases of necrotizing fasciitis, septic shock, septic arthritis, bacteremia in immunocompromised hosts, sepsis in the setting of bacteremia in dialysis patient, chronic obstructive pulmonary disease, hypertension and diabetic patients, peritonitis, chronic respiratory tract infection in patients with cystic fibrosis and meningoencephalitis [2-8].

Diagnosis need imaging and cultures with special preparations. Growth on MacConkey agar is usually detectable within 24 hours of inoculation which is a commonly used media in laboratory for gram negative bacilli. It usually also shows growth on blood and chocolate agar in 24-48 hours at incubation temperature of 37°C. Computed tomography (CT) is the imaging modality of choice for the diagnosis of deep neck space infections. CT allows evaluation of soft tissues and especially bones with a single exposure.

Management includes appropriate selection of antibiotics due to increased prevalence of resistant strains. Sphingobacterium multivorum is intrinsically resistant to many commonly administered antibiotics and can cause a life-threatening infection. Sphingobacterium multivorum can produce an extended-spectrum β -lactamase and at times a metallo- β -lactamase, conferring resistance to third-generation cephalosporins and carbapenems [9]. In review of the literature, the three most commonly

susceptible antibiotics were TMP/SMX, quinolones and tetracyclines.

There are different complications associated with deep neck infections if left untreated and include dysphagia and odynophagia secondary to inflammation of the cricoarytenoid joints, dysphonia and hoarseness due to involvement of the tenth cranial nerve, unilateral tongue paresis due to involvement of the twelfth cranial nerve and stridor and dyspnea which signify airway obstruction and may be manifestations of local pressure or spread of infection to the mediastinum.

Our patient was diagnosed with neck abscess aspirate culture which showed that sphingobacterium multivorum was sensitive to third generation cephalosporins, carbapenems, TMP/SMX and levofloxacin. He had resolution of symptoms during follow up in the infectious disease clinic after a course of oral antibiotics.

4. CONCLUSION

This case highlights the uncommon presentation of sphingobacterium multivorum, a gram negative bacillus as a causative agent for neck abscess in an immunocompetent individual which can be life threatening if left untreated due to the involvement of surrounding structures. Clinicians should consider sphingobacterium multivorum as possible cause of localized neck abscess even in immunocompetent hosts and should work up for it accordingly.

CONSENT

As per international standard or university standard, patient's written consent has been collected and preserved by the authors.

ETHICAL APPROVAL

It is not applicable.

COMPETING INTERESTS

Authors have declared that no competing interests exist.

REFERENCES

1. Naka T, Fujiwara N, Yano I, Maeda S, et al. Structural analysis of sphingophospholipids derived from

- Sphingobacterium spiritovorum, the type species of genus Sphingobacterium. Biochim Biophys Acta. 2003;1635:83–9. DOI:10.1016/j.bbalip.2003.10.010
2. Hibi A, Kumano Y. Sphingobacterium spiritovorum bacteremia due to cellulitis in an elderly man with chronic obstructive pulmonary disease and congestive heart failure: A case report. J Med Case Rep. 2017;11:277. DOI:10.1186/s13256-017-1445-6
 3. Marinella MA. Cellulitis and sepsis due to Sphingobacterium. JAMA. 2002;16:1985. DOI:10.1001/jama.288.16.1985-a
 4. Mendes, Cavallo RR, Carvalhães CH, Ferrarini MA. Septic arthritis by Sphingobacterium multivorum in immunocompromised pediatric patient. Rev Paul Pediatr. Epub. 2016;34:379-83. DOI:10.1016/j.rpped.2015.12.001
 5. Barahona F, Slim J. Sphingobacterium multivorum: Case report and literature review. New Microbes New Infect. 2015; 7:33-36. DOI:10.1016/j.nmni.2015.04.006
 6. Lambiase A, Rossano F, Del Pezzo M, et al. Sphingobacterium respiratory tract infection in patients with cystic fibrosis. BMC Res Notes. 2009;2:262. DOI:10.1186/1756-0500-2-262
 7. Reina J, Borrel N, Figuerola J. Sphingobacterium Multivorum isolated from a patient with cystic fibrosis. Eur J Clin Microbiol Infect Dis. 1992;11:81–82. DOI:10.1007/BF01971283
 8. Verma RK, Rawat R, Singh A, et al. Sphingobacterium Multivorum causing fatal meningoencephalitis. A rare case report. Int J Res Med Sci. 2014;2:1710-1712. DOI:10.5455/2320-6012.ijrms20141189
 9. Blahová Králiková K, Krcmery V Sr, Kubonová K. Hydrolysis of imipenem, meropenem, ceftazidime, and cefepime by multiresistant nosocomial strains of Sphingobacterium Multivorum. Eur J Clin Microbiol Infect Dis. 1997;2:178–80. DOI: 10.1007/BF01709484

© 2018 Khalid et al.; This is an Open Access article distributed under the terms of the Creative Commons Attribution License (<http://creativecommons.org/licenses/by/4.0>), which permits unrestricted use, distribution, and reproduction in any medium, provided the original work is properly cited.

Peer-review history:

The peer review history for this paper can be accessed here:

<http://www.sciencedomain.org/review-history/24984>