



Relating Mandibular Incisor to the Lingual Frenum in Dentulous and Edentulous (Complete Denture Wearers) Subjects: An *in vitro* Study

Kaushik Kumar Pandey^{1*}, Mariyam Ali¹, Ashok Kumar Verma¹,
Saurabh Chaturvedi², Naeem Ahmad¹ and Krishna Deo¹

¹Department of Prosthodontics, Career Post Graduate Institute of Dental Sciences, Lucknow, India.

²King Khalid University, College of Dentistry, Abha, Saudi Arabia.

Authors' contributions

This work was carried out in collaboration between all authors. Author KKP designed the study, wrote the protocol, and wrote the first draft of the manuscript. Author MA managed the literature searches. Author AKV handled the analyses of the study and author SC managed the laboratory procedures while author NA did the final formatting. Author KD did the proof reading. All authors read and approved the final manuscript.

Article Information

DOI: 10.9734/BJMMR/2016/20457

Editor(s):

(1) Joao Paulo Steffens, Department of Dentistry, University of Uberaba, Brazil.

Reviewers:

(1) Sandeep Kumar, JCD dental college, Sirsa, India.

(2) Jaspinder Kaur, Guru Nanak Dev Dental Hospital, Punjab, India.

Complete Peer review History: <http://sciencedomain.org/review-history/12035>

Original Research Article

Received 28th July 2015
Accepted 6th October 2015
Published 30th October 2015

ABSTRACT

Aim and Objectives: This study is determined the vertical distance between lingual frenum and incisal edge of mandibular central incisors in dentulous subject and edentulous denture wearer subjects and their variation in different age groups and sex.

Materials and Methods: This study involved 120 dentulous subjects (60 men, 60 women) and 20 complete denture wearers. Depending upon the age, the dentulous subjects were divided into three groups. Each group consisted of 40 subjects (20 men, 20 women). Group I consisted of 20-30 yr age, group II 30-40 yr age and group III consisted of more than 40 yr age. Mandibular impressions of dentulous and denture wearers were made with irreversible hydrocolloid and cast retrieved. The vertical distance between the anterior attachment of lingual frenum and incisal edges of the mandibular central incisors for both the dentulous and edentulous subjects was measured on the casts with the help of dental surveyor. Data were tabulated and statically analysed.

*Corresponding author: E-mail: Kaushik.pandey05@gmail.com;

Results: Overall (irrespective of gender) normative range for vertical distance between the anterior attachment of the lingual frenum and mesioincisal edge of mandibular central incisor among dentulous subjects is 9.52-10.24 mm. If we consider gender it is 10.00-11.13 mm for male and 8.82-9.58 mm for female.

Conclusion: This study indicated that the distance between the antero-superior most point on the lingual frenum and the mesio-incisal edges of mandibular central incisors can be used as a reliable landmark when the frenum is recorded during function.

Keywords: Lingual frenum; vertical positioning; complete denture; mandibular incisors.

1. INTRODUCTION

Esthetics can be defined as “pertaining to the study of beauty and the sense of beautiful”. The restoration of natural and pleasing lip support is one of the prime requisites of an esthetic denture. Denture esthetics is defined as ‘*the cosmetic effect produced by a dental prosthesis which affects the desirable beauty, attractiveness, character, and dignity of the individual*’ [1].

Pound stated “*anterior and posterior teeth should be placed in the same natural position from which they came, relative to lips, cheeks, and tongue*” [2]. Hence, the knowledge of natural tooth position would be valuable as a starting point in establishing anterior tooth position for most of the complete denture patients [3]. Placing teeth in these positions results in enhanced esthetics, phonetics and denture stability. The determinants of incisal guidance are esthetics, phonetics, condylar border movements, positional relationships of maxillary and mandibular anterior teeth [4]. All these factors are interrelated, still, there is no universally accepted scientifically proven single accurate method, due to variation in the physical characteristics of individuals for the determination of above factors. Therefore establishing more guidelines with the use of reliable pre-extraction records would be of great assistance in determining these factors more accurately.

It is documented that in lower arch, lingual frenum seems to be a stable landmark. Lingual frenum can be recorded in function until ridge is not severely resorbed. The lingual frenum is a thin sheet of fibrous connective tissue that attaches the centre of the ventral surface of the tongue to the floor of the mouth. It is located in the midline lingual to the mandibular central incisors. In the edentulous condition, it attaches to the lingual aspect of the mandibular ridge in the midline [5]. It is well documented that mandibular anterior teeth are displayed to a

greater extent than the maxillary anterior teeth in various facial expressions. Most literature related to positioning of artificial anterior teeth, emphasize more on the positions of maxillary teeth and little information is available regarding the positions of mandibular anterior teeth even though there is gradual reduction in the amount of maxillary anterior teeth exposure with an increase in age, accompanied by gradual increase in mandibular anterior teeth exposure [6]. So this study was performed to establish a relationship between lingual frenum and incisal edge of mandibular central incisor.

Hence, this study was undertaken with the aim to relate mandibular incisor to the lingual frenum in dentulous and edentulous (complete denture wearers) subjects. Objectives of the study were: (1) To determine the variation with age and sex in relative vertical distance between lingual frenum and incisal edge of mandibular central incisors (2) To compare the values among dentulous subjects and complete denture wearers.

2. MATERIALS AND METHODS

The materials used were irreversible hydrocolloid (Zelgan, dentsply, India) for making impression and type III gypsum (Prevest denpro, India) product for pouring the cast. Instruments used were dental surveyor (Unident, India), cast paralleling device and digital vernier caliper.

2.1 Data Collection

The study involved 120 dentulous subjects (60 men, 60 women) and 20 complete denture wearers. Dentulous subjects had following inclusion criteria; aligned full complement of natural permanent teeth up to II molar, angle class I maxillomandibular relationship, well traceable lingual frenum and mild attrition of canine cusp tip and central incisal edge in age group of 45-60.

Exclusion criteria for dentulous subjects were; Subjects having class II and class III ridge

relationship, ankyloglossia, any parafunctional habits, any restoration and/or prosthetic, orthodontic treatment in mandibular anterior region, missing and supraerupted central incisors, canine in the mandibular arch, moderate and /or severe attrition or any pathologic wear of mandibular anterior teeth, maxillofacial trauma.

Inclusion criteria for edentulous subjects were; Subjects should be successful complete denture wearers without any complain regarding mastication, esthetics and phonetics. Denture border extension should be proper. Denture samples incorporated in study should have recorded full length lingual frenum and have 'V' shaped lingual flange. Subjects should have class I ridge relationship. Exclusion criteria for edentulous subjects were; Denture should not be Worn-out and broken. Dentures should not be more than one year old.

On the basis of age, presence or absence of teeth, subjects were divided into four groups: D2030, D3040, Dab40, EDW (Table 1). For dentate subjects, the selected trays were adjusted before impression making, so that the lingual flange of the tray was approximately 2 to 3 mm short of the movable tissues of the floor of the mouth (Fig. 1, Fig. 2). Impressions were taken with Irreversible hydrocolloid impression material (Zelgan, dentsply, India) and subjects were instructed to elevate the tongue and moisten the upper lip with the tip of the tongue (Fig. 3, Fig. 4, Fig. 5). Impressions were poured using type III gypsum (Prevest denpro, India) product. For edentulous subjects impression of the lower arch was made with mandibular denture in position and the denture was separated from the impression and returned to the subject. Remaining methodology was same as with dentate subjects. Casts/models of both dentulous and edentulous subjects were retrieved for analysis (Fig. 6, Fig. 7, Fig. 8, and Fig. 9).




Fig. 1. Overextended lingual flanges of perforated stock tray were shortened by trimming using a metal trimmer



Fig. 2. Under extended flanges of perforated stock tray were extended with impression compound

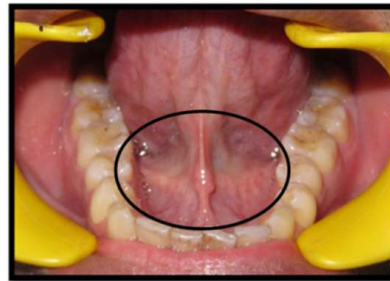

Fig. 3. Activated lingual frenum in dentulous subjects

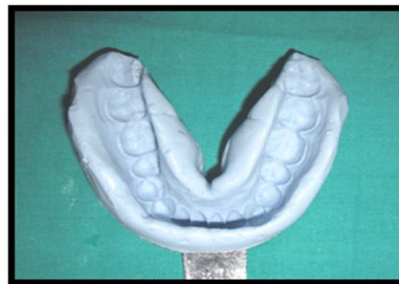

Fig. 4. Irreversible hydrocolloid impression of activated lingual frenum in dentulous subjects

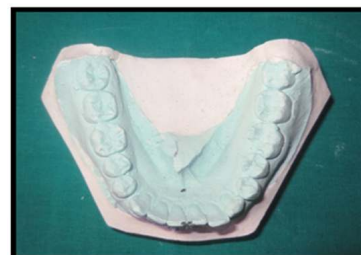

Fig. 5. Mandibular cast of dentulous subjects

2.2 Method of Measurement of Vertical Distance between Anterior Attachment of Lingual Frenum (AALF) and Incisal Edge of Mandibular Central Incisor (CI) on Cast

Point markings were made on cast by using sharp carbon marker tip, one on the mesioincisal angle of central incisors and a second point was marked on the anterior attachment of the lingual frenum. For paralleling the occlusal plane to horizontal plane, a cast paralleling device consisting of flat plate with central metal rod in centre at 90° was attached to the Jelenko Surveyor. The cast holder was tilted until the teeth established contact with the plate on at least three widely divergent points one anteriorly and two posteriorly on both the sides (Fig. 10, Fig. 11). The surveying arm with analyzing rod was lowered until the tip of the analyzing rod contacted the mark on the anterior attachment of the lingual frenum. A horizontal mark was made with a pointed pen on the vertical arm of the surveyor where it met the horizontal arm. Similarly, a second horizontal mark was made on the vertical arm of the surveyor where it met the horizontal arm, when the tip of the analyzing rod was made to contact the mark on the mesioincisal angle of central incisors (Fig. 12, Fig. 13). The distance between two horizontal marks on the vertical arm of the surveyor was measured using a digital vernier calliper (Fig. 14).

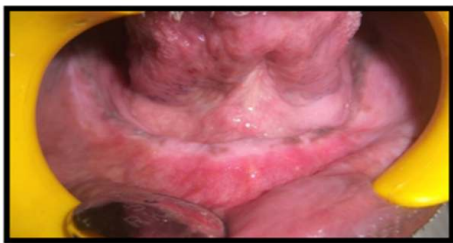

Fig. 6. Activated Lingual frenum in edentulous subjects

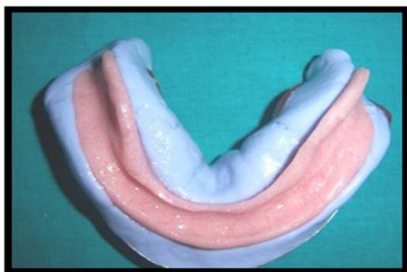


Fig. 7. Irreversible hydrocolloid impression with denture

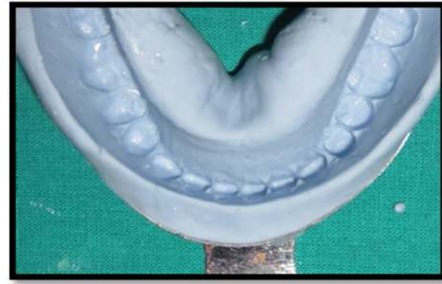


Fig. 8. Irreversible hydrocolloid impression without denture

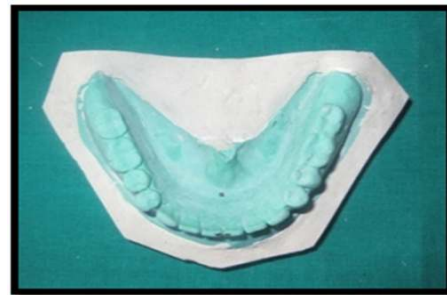

Fig. 9. Mandibular cast with denture in edentulous subjects

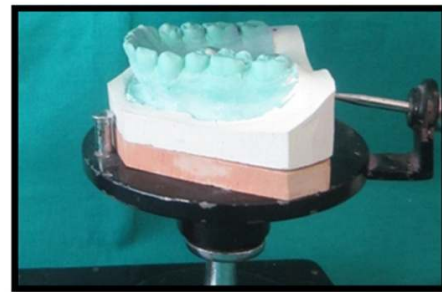


Fig. 10. Mandibular cast of dentulous subjects attached on surveying table using die stone block




Fig. 11. Cast paralleling device adjusted the tilt of the cast

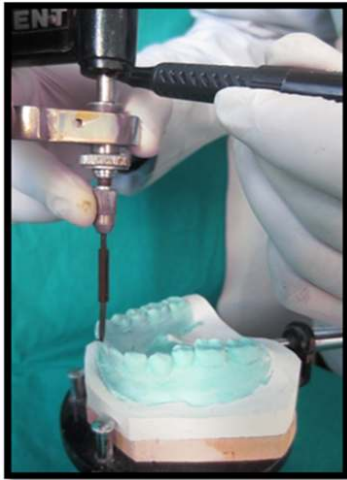


Fig. 12. Marking done on vertical arm when analysing rod made to contact the mark on incisal edge of central incisor

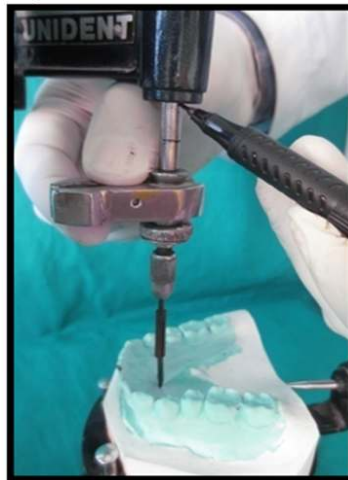


Fig. 13. Second marking on vertical arm done when analyzing rod made to contact the mark on anterior attachment of lingual frenum



Fig. 14. The distance between two horizontal marks on the vertical arm of the surveyor was measured using a digital vernier caliper

Table 1. Group wise distribution of subjects

Group	Description	No. of subject
D2030	Dentulous subjects aged between 20 and 30 year	20 male and 20 female
D3040	Dentulous subjects aged between 30 and 40 years	20 male and 20 female
Dab40	Dentulous subjects aged above 40 years	20 male and 20 female
EDW	Edentulous complete denture wearer	20 (both gender combined)

3. RESULTS

All the readings obtained were tabulated and statistically analyzed. For overall as well as for both the genders for Group D2030, Group D3040 and Group D ab40, statistically no significant differences were observed among different age groups i.e. $p > 0.05$. Hence, a common normative range could be derived for all age groups, i.e. the vertical distance showed remained unchanged with change in age (Table 2, Graph 1).

For overall dentulous subjects (total of subjects in Group D2030, Group D3040 and Group Dab40) vertical distance values ranged from 6.02 to 15.78 mm with a mean value of 9.88 and standard deviation of 1.98 mm. Median value was 9.70 mm. The normative range (95% CI) was 9.52-10.24 mm sex. In males, vertical distance values ranged from 6.02 to 15.78 mm with a mean value of 10.56 and standard deviation of 2.18 mm. Median value was 10.59 mm. The normative range (95% CI) was 10.00-11.13 mm. In females, vertical distance values ranged from 6.23 to 12.44 mm with a mean value

of 9.20 and standard deviation of 1.48 mm. Median value was 9.13 mm. The normative range (95% CI) was 8.82-9.58. On comparing the vertical distance values between two genders the difference between two groups was significant statistically ($p < 0.001$), thus indicating that a common normative range cannot be used as a representative of both the genders (Table 3).

After comparing the mean vertical distance between anterior attachment of lingual frenum and incisal edge of mandibular central between edentulous denture wearers (Group EDW) and dentulous subjects belonging to more than 40 year age group (Group Dab40). We found that a significant difference between edentulous denture wearers and dentulous subjects was observed for age group >40 years ($p = 0.021$) (Table 3).

4. DISCUSSION

Placing the artificial teeth so as to convey the most natural appearance may be regarded as an expression of the artistic talent of the dentist. According to Frush and Fisher, pleasing lip

support for an edentulous patient is achieved by the correct placement of the anterior teeth and their matrix [7]. Boucher also subscribed to the same point of view. "Set the teeth where they grew" was postulated by Payne [8].

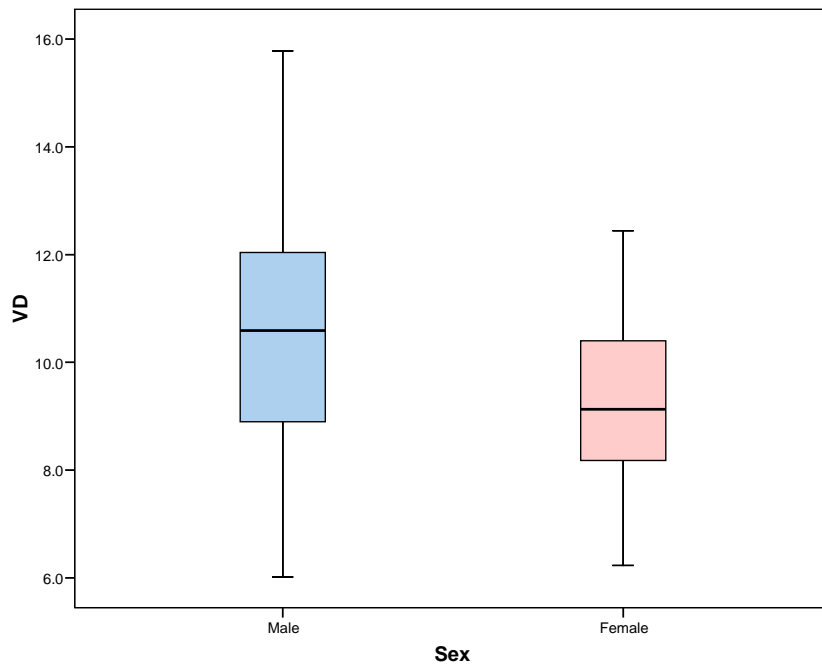
Nature's method of tooth placement and contour of tissues results in more esthetic appearance, more comfort and satisfaction to the patient [9]. But the problem is to relocate the natural teeth position when fabricating artificial dentures.

Most of the studies either giving importance to maxillary anterior teeth or related to positioning of maxillary anterior teeth give information regarding the anterioposterior positioning of the maxillary central incisors [10,11]. The incisive papilla has been proved to be the most obvious landmark that appears to have survived intact from the dentate state, and it has received a great deal of attention [12]. But, little information is available regarding the positioning of mandibular anterior teeth and thus, has been

Table 2. Summary statistics of vertical measurements between anterior attachment of lingual frenum and incisal edge of mandibular central incisor of dentulous subjects in all age groups

S_no.	Statistic	Total (n=120)	Males (n=60)	Females (n=60)
1.	Minimum	6.02	6.02	6.23
2.	Maximum	15.78	15.78	12.44
3.	Mean	9.88	10.56	9.20
4.	SD	1.98	2.18	1.48
5.	Median	9.70	10.59	9.13
6.	95% CI Lower	9.52	10.00	8.82
	Upper	10.24	11.13	9.58

$t=4.012; p<0.001$



Graph 1. Summary statistics of vertical measurements in dentulous subjects in all age groups

Table 3. Comparison of mean vertical distance between edentulous denture wearers and dentulous subjects aged >40 years (Both genders combined)

Edentulous denture wearers (Group: EDW)			Dentulous subjects (Group: Dab40)			Statistical significance	
n	Mean	SD	n	Mean	SD	"t"	"p"
20	10.82	2.57	40	9.41	1.95	2.371	0.021

inadequately researched so far. Silverman S. (1967) showed that during phonation, people usually display more of the mandibular anterior teeth than the maxillary anterior teeth [13].

Vig and Brundo (1978) focused on the visibility of natural maxillary and mandibular teeth. They suggested that mandibular arch was found to play a greater role than previously being mentioned in the literature [14]. Cade R. E. (1979) showed that mandibular anterior teeth do play an important role in patients appearance. The mandibular anterior teeth were displayed to a greater extent than the maxillary anterior teeth in various facial expressions [6].

I have included the edentulous denture wearer subjects (Group EDW) just to check the errors in vertical positioning of mandibular anterior teeth during teeth setting. When I have compared edentulous denture wearer subjects with dentulous subjects belonging to more than 40 year age group (Group Dab40), I found there is statistically significant difference i'e there must be some errors in teeth setting of the dentures. So if, we take guideline from our study and place mandibular anterior teeth accordingly: It will affect esthetics, phonetics and stability of mandibular denture.

Lingual frenum is a small muscle which attaches the tongue to the bone and the attachment of lingual frenum does not undergo changes, even after exfoliation/ extraction of teeth [5]. Keeping this in mind, the present study was undertaken to establish a stable mandibular landmark for positioning of mandibular anterior teeth. In this present study, the mandibular lingual frenum has been taken as the landmark to assess its vertical relationship with incisal edge of mandibular central incisors. Subjects with attrition, erosion, midline deviation of dentition, abnormalities of tongue and teeth were excluded so as to get a standardized value with minimal standard deviation. In this study, dentulous subjects with Angle's class I molar relation were considered, as it represents most stable occlusion. Hence dentulous subjects with Angle's class II and class III molar relation were not included.

In the present study, the last natural permanent tooth of the whole arch was second molar as it represents full eruption period. Dentulous subjects with abnormal freni conditions like tongue tie were not involved in this study as we have to record the anterior attachment of lingual frenum during impression making and it became

difficult for the patient to elevate the tongue and moisten the upper lip with the tip of the tongue in the tongue tie situations. The mesioincisal angle was taken as measuring point as it lies in direct vertical midline relation with the lingual frenum. The armentarium used for the cast paralleling device was kept simple and one which is easily available in every dental office. The occlusal plate was modified to form an orientation device for cast. The impression was taken with irreversible hydrocolloids in stock trays. This method is simple, does not necessitate taking extra steps, and is not expensive. The method of measurement used in this study for calculating the vertical distance between the anterior attachment of the lingual frenum and the mesioincisal edge of mandibular central incisors has been in accordance with Majid Bissasu [15], Guldag MU [16] and Hanan A. Rahman [17].

Majid Bissasu concluded in his study that measurement of the distance between the anterior attachment of lingual frenum (AALF) and the incisal edges of mandibular incisors is reliable when the frenum is recorded during function. The position of the AALF can be considered a relatively stable anatomic landmark when the frenum is recorded during function. The distance between the AALF and the incisal edges of the mandibular central incisors can be used on preextraction diagnostic casts, made from irreversible hydrocolloid impression material in stock trays, as a preextraction record for determining the original vertical position of the mandibular anterior teeth. So if we use the finding of this study, a more accurate position for mandibular anterior teeth can be achieved in terms of height and antero-posterior positioning of the tip of mandibular incisors resulting in a more natural esthetic value [15,18-20].

5. CONCLUSION

This study indicated that the distance between the most antero-superior point on the lingual frenum and the mesio-incisal edges of mandibular central incisors can be used as a reliable landmark when the frenum is recorded during function. Overall (irrespective of gender) normative range for vertical distance between the anterior attachment of the lingual frenum and mesioincisal edge of mandibular central incisor among dentulous subjects is 9.52-10.24 mm. If we consider gender it is 10.00-11.13 mm for male and 8.82-9.58 mm for female. When the teeth have been set by the laboratory technician according to the work authorization, the dentist

can apply these measurements to judge the conformation and position of the artificial mandibular central incisors. Further studies are needed to locate or mimic the correct natural vertical position of mandibular anterior teeth during the arrangement of the artificial teeth for complete denture fabrication.

CONSENT

It is not applicable.

ETHICAL APPROVAL

Ethical approval was taken from institutional ethical research cell committee.

COMPETING INTERESTS

Authors have declared that no competing interests exist.

REFERENCES

1. Winkler S. Essentials of complete denture prosthodontics. Second edition. 2009;202.
2. Pound E. Lost- fine arts in fallacy of the ridges. J Prosthet Dent. 1954;4:6-16.
3. Smith DE. The reliability of pre-extraction records for complete dentures. J Prosthet Dent. 1971;25:592-608.
4. Broderson SP. Anterior guidance - The key to successful occlusal treatment. J Prosthet Dent. 1978;39:396-400.
5. Michael E. Northcutt. The lingual frenum. J Clin Onco. 2009;9:557-65.
6. Cade RE. The role of the mandibular anterior teeth in complete denture esthetics. J Prosthet Dent. 1979;42:368-70.
7. Frush JP. Fisher RD. Dynesthetic interpretation of the dentogenic concept. J Prosthet Dent. 1958;8:558-81.
8. Payne SH. The try-in. D. Clin. N America. 1960;333-42.
9. McGee GF. Tooth placement and base contour in denture construction. J Prosthet Dent. 1960;10:651-58.
10. Erlich J, Gazit E. Relationship of the maxillary central incisor and canines to the incisive papilla. J Oral Rehabil. 1975;2:309-12.
11. Philip SB. Relationship of denture cast measurements to width of maxillary anterior teeth. J Prosthet Dent. 2010;105:44-50.
12. Harper RN. The incisive papilla. J Dent Res. 1948;27:661-8.
13. Silverman MM. The speaking method in measuring vertical dimension. J Prosthet Dent. 1953;3:193-199.
14. Vig RG, Brundo GC. The kinetics of anterior tooth display. J Prosthet Dent. 1978;39:502-04.
15. Bissasu M. Use of lingual frenum in determining the original vertical position of mandibular anterior teeth. J Prosthet Dent. 1999;82:177-81.
16. Guldag MU, Sentut F, Buyukkapan US. Investigation of vertical distance between incisive papilla and incisal edge of maxillary central incisors. Eur J Dent. 2008;2:161-66.
17. Rahman HA, Abdul Allah ZS, Ali Hussein BM. Evaluation of the relation between occlusal vertical dimension with lingual frenum and depth of mucolingual reflection in Iraqi adult sample. J Bagh Coll Dentistry. 2009;21:44-7.
18. Prasad KD, Alva H. Use of frenum in determining the original vertical position of teeth. J Oral Health Comm Dent. 2013;7(1):44-46.
19. Himanshu A, Pradeep K, Rubina G, Anubha A. Relationship of labial & lingual frenum to the height of mandibular central incisors. Ind J Dent Scien. 2015;7(2):1-5.
20. Balasubramanian R, Leoney A, Krishna R. An *in vivo* correlation analysis of the distance between lingual frenal attachment and mandibular incisal edge position as an aid in establishing mandibular occlusal plane in South Indian population. 2015;9(2):54-57.

© 2016 Pandey et al.; This is an Open Access article distributed under the terms of the Creative Commons Attribution License (<http://creativecommons.org/licenses/by/4.0>), which permits unrestricted use, distribution, and reproduction in any medium, provided the original work is properly cited.

Peer-review history:

The peer review history for this paper can be accessed here:
<http://sciedomain.org/review-history/12035>